



E-ISSN: 2320-7078

P-ISSN: 2349-6800

www.entomoljournal.com

JEZS 2021; 9(1): 1258-1261

© 2021 JEZS

Received: 01-11-2020

Accepted: 03-12-2020

Rohit Kumar TiwariTeaching Associate, Veterinary
University Training and
Research Centre, Kumher,
Bharatpur, Rajasthan, India**Vikas Galav**Assistant Professor, Dept of
Veterinary Pathology, PGIVER,
Jaipur, Rajasthan, India**Sandeep Kumar Sharma**Assistant Professor, Dept of
Veterinary Microbiology,
PGIVER, Jaipur, Rajasthan,
India**Sandeep Marodia**Assistant Professor, Dept of
Veterinary Clinical Complex,
ACVM, Jaipur, Rajasthan, India**Brajesh Kumar**Assistant Professor, Dept of
Veterinary Pathology, ACVM,
Jaipur, Rajasthan, India**Manish Agrawal**Assistant Professor, Dept of
Veterinary Pathology, PGIVER,
Jaipur, Rajasthan, India**Corresponding Author:****Vikas Galav**Assistant Professor, Dept of
Veterinary Pathology, PGIVER,
Jaipur, Rajasthan, India

Occurrence and aetio-pathological study on interstitial pneumonia of sheep (*Ovis aries*)

Rohit Kumar Tiwari, Vikas Galav, Sandeep Kumar Sharma, Sandeep Marodia, Brajesh Kumar and Manish Agrawal

Abstract

The present study was conducted to evaluate the interstitial pneumonia associated with the bacterial aetiology in sheep from Jaipur Division, Rajasthan. A total of 436 lungs were examined of which 102 lungs (23.40%) found with gross lesions were collected intact for the study. For bacteriological examination, swabs were collected at site of lesion from within tissue parenchyma under sterile conditions. Of the total 102 sheep lungs with clear gross lesions, 79 (77.45 %) lungs were found to harbor bacteria. For pathomorphological evaluation, only those lungs (79) that were found infected with bacteria were considered. Interstitial pneumonia was noticed in 21 (26.50 %) cases. Grossly, lungs were pale to red, heavy and firm, rubbery and cut surface had a meaty appearance and showed frothy exudate from the incised bronchi and bronchioles. Rib impressions were also observed over the costal surface of diaphragmatic lobes. Microscopically, the alveoli were distorted in shape, alveolar septae was thickened with infiltration of mononuclear cells and macrophages. At some places, the alveolar epithelium revealed foetalization with hyperplasia of type-II pneumocytes. In present study, bacteria isolated from lungs with interstitial pneumonia were *Staphylococcus* spp, *Streptococcus* spp, *Pseudomonas* spp, *E. coli*, *Enterobacter* spp and *Klebsiella* spp. mostly as mixed infections with no definite preference to single bacterial specie.

Keywords: bacteria, histopathology, lungs, pneumonia, sheep

Introduction

Sheep and goats were perhaps the first ruminants to be domesticated by man. Sheep is an important economic animal, which is domesticated by people worldwide. Sheep suits to the need of small land holders and village system due to low initial investment, ease of rearing and high feed conversion efficiency. Besides this, they are very well adapted to harsh climate, long migration, resistance to tropical diseases, poor nutrition, shortage of drinking water and water quality. Among various causes of production losses in sheep and goat industry, losses due to infectious diseases are major contributors, which cause decrease in weight gain, milk yield, meat, wool production and high mortality among kids and lambs [1]. Among pathological conditions diarrhea and pneumonia are most common causes of mortality in small ruminants [2]. Pneumonia in sheep is associated with a wide range of infectious agents, which includes bacterial, viral, fungal and parasitic agents. Bacterial pneumonias are most common and they may act as a primary or secondary cause to it [3, 4]. Pneumonia in sheep and goats is classified according to the involvement of different pulmonary regions and anatomical sites, and nature of the inflammatory exudate and reaction present [5, 6]. The alteration in the homeostatic environment of the lung parenchyma due to stressors like physiological/environmental stress, decreased immunity, infectious pathogens and the environmental pollutants lead to the development of the pneumonia [7]. So the etio-pathological study of respiratory system is very important, as lungs diseases bear a major segment of total burden of sheep diseases and considered the most important cause of illness and death. The studies of various pathological conditions of respiratory system are important for the pathologist, to understand the altered structure, disturbed function and related clinical outcome.

Material and Methods

A. Source And Collection Of Samples

The tissue specimens of lungs for the proposed investigation were collected from various slaughter houses and meat sales outlets of Jaipur Division, Rajasthan.

The tissue samples were also collected from sheep carcasses received from institutional farm and field for the post-mortem examination at Department of Veterinary Pathology, PGIVER, Jaipur. During post-mortem examination, whole lungs from sheep carcass were thoroughly examined grossly for any alterations in morphology in terms of shape, size, color, consistency, location and presence of cysts, tumors and abscesses, other growths and lesions etc. as screened by visual examination and gross palpation. Those grossly indicative of pathology were collected and put into sterile polythene bag and transported on ice pack to the laboratory. For bacteriological examinations the surface of the lung was cleaned by 70 percent ethanol under laminar hood. The lungs were incised using sterilized scalpel and swabs were collected from tissue parenchyma at site of lesions for microbial culture. A total of 436 sheep lungs were examined, out of which 102 sheep lungs with gross damage were employed in the study.

B. Processing Of Tissue Samples

Following collection of swabs for microbial culture, all the lung samples were preserved in 10 percent buffered formal saline. Representative tissue sample was incised from affected parenchyma measuring about 2-5 mm in thickness and presenting the lesions alongside normal tissue for further histopathological processing. The tissue samples were processed mechanically by standard processing technique⁽⁸⁾. Tissue pieces were dehydrated, cleared and following paraffin embedding, 4-6 micron thick sections were cut using manual microtome (HM 325, Thermo Shandon). Tissue ribbons were mounted over albuminized slides for histological staining.

C. Staining Of Tissue Sections

The tissue sections were stained using standard haematoxylin and eosin method. Following deparaffinization, the sections were hydrated using serial changes in ethanol and stained using harris haematoxylin. After differentiation and follow up staining with Eosin, the slides were dehydrated and then permanently mounted using DPX^[9, 10].

D. Bacterial Isolation, Identification And Phenotypic Characterization

For aetio-pathological correlation, swabs collected from lung lesions were streaked over (i) Mannitol Salt Agar (MSA), (ii) Edward's Medium Agar, (iii) MacConkey Agar MCA) and (iv) Cetrimide Agar plates and thereafter incubated for 24 hrs at 37 °C. The MSA and Edwards medium were employed to target the gram positive bacterial pathogens (*Staphylococcus* spp. and *Streptococcus* spp.) and those of MCA and Cetrimide were employed to target the gram negative bacterial pathogens including those from *Enterobacteriaceae* (*Pseudomonas* spp., *Enterobacter* spp., *Escherichia coli* and *Klebsiella* spp.). Post 24 hrs incubation, bacterial colonies were closely observed for their morphology, colour and consistency. Gram's staining was used as primary identification test. Biochemical and secondary metabolic tests including hemolysis test was also conducted using standard methods^[11, 12].

Results and Discussion

The tissue specimens of lungs for the proposed investigation were collected from various slaughter houses, field postmortems and meat sales outlets of Jaipur, Rajasthan. Out of 436 total lungs examined, only 102 lungs (23.40%) found

with gross lesions. Of the 102 lungs found with gross lesions, 79 affected lungs (77.50%) were positive for bacterial isolation and for correlative study only those were considered for pathomorphological assessment.

The incidence of the inflammatory conditions was 84.80% (67 out of 79) in the present study which constituted various types of pneumonia and pleuritis. In present study, occurrence of interstitial pneumonia was reported at frequency of 26.50% (21 out of 79). These findings in sheep are higher than most of the other studies which included reported occurrence of 23.61%^[13], 16.41%^[14, 15], 15%^[16], 7.88%^[17], 7%^[18] and 2.67%^[19] in sheep lungs.

In present study, on gross observation, lungs were pale to red, heavy and firm, rubbery and in certain cases failed to collapse (Fig. 1). Cut surface had a meaty appearance and showed frothy exudate from the incised bronchi and bronchioles (Fig. 2). Rib impressions were also observed over the costal surface of diaphragmatic lobes.

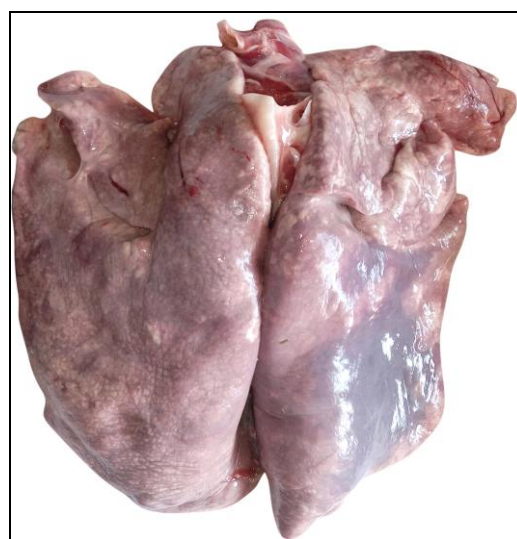

Fig 1: Gross Picture Showing Hard, Firm, Enlarged Lungs with Dark Red Areas: Interstitial Pneumonia

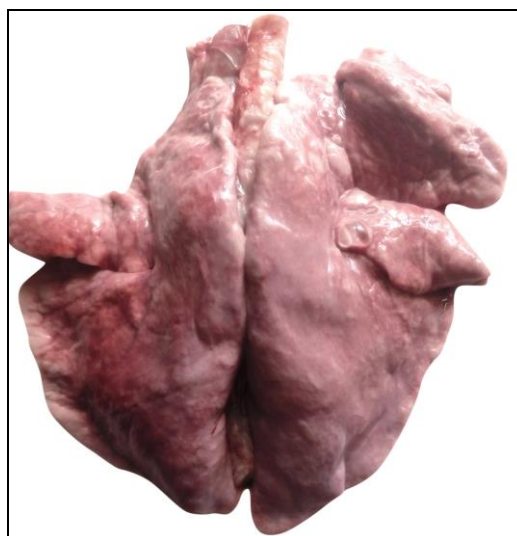


Fig 2: Gross Picture Showing Meaty, Rubberly Appearance of Lungs: Interstitial Pneumonia

Microscopically, the alveoli were distorted in shape. Alveoli linings showed increased number of cuboidal cells (Fig. 3). The alveolar interstitium septae were congested and thickened with marked infiltration of mononuclear cell, macrophages

and RBCs also at few places (Fig. 4 and Fig. 5). At some places, the alveolar epithelium revealed foetalization with hyperplasia of type-II pneumocytes. Fibrous tissue proliferation along the alveolar walls and associated alveolar fibrosis was also noticed in few sections.

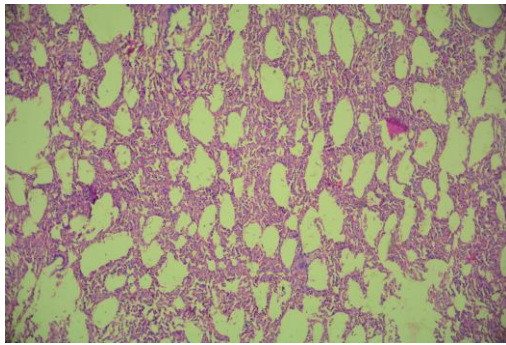


Fig 3: Microphotograph Showing Distorted Alveoli Spaces, Sheep Lung, H&E 100x

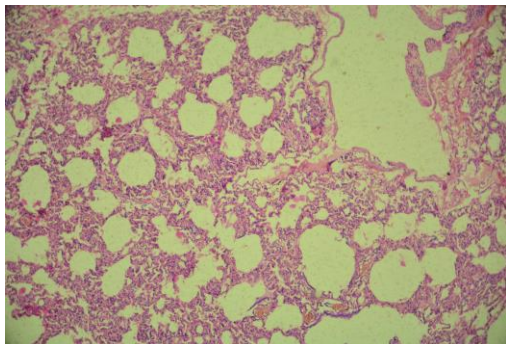


Fig 4: Microphotograph Showing Destruction of Alveolar Epithelial Lining and Thickening of Alveolar Septa, Sheep Lung, H&E 100x

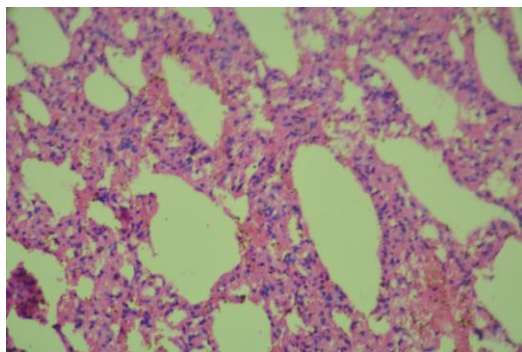


Fig 5: Microphotograph Showing Alveoli with Epithelial Damage, Thickening of Alveolar Septa, Increased RBCs and Mononuclear Engagement in Lung Parenchyma, H&E 400x

The findings of interstitial pneumonia were in close accordance with those of [16] reporting lungs that were hard on palpation and microscopically, alveolar septae were thickened due to accumulation of mononuclear cells and proliferation of fibrous connective tissue. Enlarged lungs with pale colour, rubbery consistency, oedema in alveoli and alveolar septa and hyperplasia of cells type II (epithelialization) [14] and interstitial pneumonia having pale to red, heavy and firm lungs with rib impressions and that failed to collapse when thorax was opened [20]. Alveolar septae were congested and alveoli were distorted in shape. The observations in present study were also similar to those reported by [21-23]. In present study, bacteria isolated from lungs with interstitial pneumonia were *Staphylococcus* spp, *Streptococcus* spp,

Pseudomonas spp, *E. coli*, *Enterobacter* spp and *Klebsiella* spp. Other studies have also reported isolation of similar bacterial species as reports for *Escherichia coli* [16], *E. coli*, *Pseudomonas* spp and *Staphylococcus* spp [14, 24], *Streptococcus pyogenes* and *Staphylococcus aureus* [15], *Streptococcus pneumoniae* [22], *Staphylococcus* spp [19] and *Klebsiella* spp [20, 24].

Conclusion

The current investigation unveiled that more than 26.50 % of sheep having respiratory infections in Jaipur are likely to be affected with interstitial pneumonia.

In sheep, most pulmonary diseases are diagnosed as acute however changes in lung tissue could not be ascertained. Evaluating lung tissues based on histopathology, give a confirmative assessment of various types of pneumonia in sheep and this could further be employed in various abattoirs and regional veterinary laboratories to generate additional epidemiological data for a better disease control and prevention measures. Further bacterial association of interstitial pneumonia with *Staphylococcus* spp, *Streptococcus* spp, *Pseudomonas* spp, *E. coli*, *Enterobacter* spp and *Klebsiella* spp. mostly as mixed infections provides a significant evidence of bacterial involvement in etiology and pathogenesis of interstitial pneumonia in sheep. The data generated would further assist to formulate feasible and cost-effective control strategies in sheep diseases.

Acknowledgement

We acknowledge the support and guidance provided by Dr. Vikas Galav, the Major Advisor for this piece of work at PGIVER and also DEAN, PGIVER, Jaipur for providing necessary facilities to carry out this research work.

References

1. Katoch VM. Animal Models of Tuberculosis for Vaccine Development. Indian Journal of Medical Research 2009;129:11-8.
2. Dohare AK, Singh B, Bangar Y, Prasad S, Kumar D, Shakaya G. Influence of Age, Sex and Season on Morbidity and Mortality Pattern in Goats Under Village Conditions of Madhya Pradesh. Veterinary World 2013;6:329-331.
3. Bell S. Respiratory Disease in Sheep, Treatment and control. In Practice 2008;30(5):278-283.
4. Woldemeskel M, Tibbo M, Progieter LND. Ovine Progressive Pneumonia (Maedi-Visna): An Emerging Respiratory Disease of Sheep in Ethiopia. Dtsch Tierarztl Wochenschr 2002;109(11):486-488.
5. Singh R, Kumar P, Sahoo M, Bind RB, Kumar MA, Das T. Spontaneously occurring Lung Lesions in Sheep and Goats. Indian Journal of Veterinary Pathology 2017;41(1):18-24.
6. Dar LM, Darzi MM, Mir MS, Kamil SA, Rashid A, Abdullah S. Prevalence of Lung Affections in Sheep in Northern Temperate Regions of India: A Postmortem Study. Small Ruminant Research 2013;110(1):57-61.
7. Mishra S, Kumar P, George N, Singh R, Singh V, Singh R. Survey of lung affections in sheep and goats: A slaughterhouse study. Journal of Entomology and Zoology Studies 2018;6(4):118-120.
8. Lillie RD. Histopathological technique and practical histochemistry. New York and London: Mc- Graw Hill Book Co 1965.

9. Luna G. Manual of Histological Staining of the Armed Forces Institute of Pathology. Edition 3rd, New York: McGraw Hill Book Co. 1960, 32-40.
10. Bancroft JD, Suvarna SK, Layton C. Bancroft's Theory and Practice of Histological Techniques. Edition 7th, British, Churchill Livingstone Elsevier Ltd 2013.
11. Barrow GI, Feltham RKA. Cowan and Steel's Manual for the identification of medical bacteria. Edition 3rd, Cambridge UK: Cambridge University Press 1974.
12. Quinn PJ, Carter ME, Markey BK, Carter GR. Clinical Veterinary Microbiology. Edition 1st, London: Mosby Elsevier 1994.
13. Yesuf M, Mazengia H, Chanie M. Histopathological and Bacteriological Examination of Pneumonic Lungs of Small Ruminants Slaughtered at Gondar, Ethiopia. American-Eurasian Journal of Scientific Research 2012;7(6):226-231.
14. Sayyari M, Sharma R. Pathological and bacteriological study of lobe distribution of lesions in buffalo (*Bubalus bubalis*). International Journal of Veterinary Research 2011;5(2):125-128.
15. Tijjani AN, Ameh JA, Gambo HI, Hassan SU, Sadiq MA, Gulani I. Studies on the Bacterial Flora and Pathologic Lesions of Caprine Pneumonic Lungs in Maiduguri North-Eastern Nigeria. African Journal of Microbiology Research 2012;6(48):7417-7422.
16. Ferdausi T, Haider MG, Alam KJ, Baki MA, Hossain MM. Caprine lung diseases and causal bacteria. The Bangladesh Veterinarian 2008;25(1):9-16.
17. Kumar MA, Kumar R, Varshney KC, Nair MG, Lakkawar AW, Sridhar BG *et al.* Pathomorphological Studies of Lung Lesions in Sheep. Indian Journal of Veterinary Pathology 2014;38(2):75-81.
18. Dar LM, Darzi MM, Mir MS, Kamil SA, Rashid A, Abdullah S *et al.* Histopathological and Histoenzymatic Studies on Bronchopneumonia in Sheep. Journal of Applied Animal Research 2014;42(3):289-296.
19. Azizi S, Korani FS, Oryan A. Pneumonia in Slaughtered Sheep in South-Western Iran: Pathological Characteristics and Aerobic Bacterial Aetiology. Veterinaria Italiana 2013;49(1):109-118.
20. Amaravathi M, Satheesh K, Annapurna P, Subramanyam KV. Prevalence and Aetiopathological Studies of Ovine Interstitial Pneumonia. International Journal of Advanced Research in Biological Sciences 2016; 3(3):208-210.
21. Emikpe BO, Jarikre TA, Eyarefe OD. Retrospective Study of Disease Incidence and Type of Pneumonia in Nigerian Small Ruminants in Ibadan, Nigeria. African Journal of Biomedical Research 2013;16(2):107-113.
22. Kumar A, Verma AK, Sharma AK, Rahal A. Isolation and Antibiotic Sensitivity of Streptococcus pneumonia Infection with Involvement of Multiple Organs in Lambs. Pakistan Journal of Biological Sciences 2013;16(24):2021-2025.
23. Obaid AH, Khudair ZW. The Role of Klebsiella Pneumonia for Effect on Pneumonia in the Sheep. Kufa Journal for Veterinary Medical Sciences 2016;7(2):158-175.
24. Tiwari RK, Galav V, Sharma SK, Galav A, Kumar B, Marodia S *et al.* Aetio-Pathology of Bronchopneumonia in Sheep (*Ovis aries*). Ruminant Science 2019;8(2):217-220.