



E-ISSN: 2320-7078

P-ISSN: 2349-6800

[www.entomoljournal.com](http://www.entomoljournal.com)

JEZS 2020; 8(5): 820-823

© 2020 JEZS

Received: 01-07-2020

Accepted: 03-08-2020

**J Umamageswari**

Department of Clinics, Madras  
Veterinary College, Tamil Nadu  
Veterinary and Animal Sciences  
University (TANUVAS),  
Chennai, Tamil Nadu, India

**S Balasubramanian**

Directorate of Clinic, Veterinary  
College Campus, TANUVAS,  
Chennai, Tamil Nadu, India

**K Krishnakumar**

Department of Veterinary  
Gynaecology and Obstetrics,  
Madras Veterinary College,  
TANUVAS, Chennai,  
Tamil Nadu, India

**SP Preetha**

Department of Veterinary  
Pharmacology and Toxicology,  
Madras Veterinary College,  
TANUVAS, Chennai,  
Tamil Nadu, India

**K Vijayarani**

Department of Bioinformatics  
Madras Veterinary College,  
TANUVAS, Chennai,  
Tamil Nadu, India

**Corresponding Author:****J Umamageswari**

Department of Clinics, Madras  
Veterinary College, Tamil Nadu  
Veterinary and Animal Sciences  
University (TANUVAS),  
Chennai, Tamil Nadu, India

## A simple and rapid staining technique to confirm mating in Wistar rats

**J Umamageswari, S Balasubramanian, K Krishnakumar, SP Preetha and K Vijayarani**

**DOI:** <https://doi.org/10.22271/j.ento.2020.v8.i51.7612>

**Abstract**

A simple and rapid staining technique was developed to confirm mating in Wistar rats. The study involves collection of vaginal smear from six adult female Wistar rats and the stages of the estrous cycle were determined by vaginal exfoliative cytology technique using Field stains. The Vaginal epithelial cells are classified as basal, intermediate, superficial intermediate, superficial and cornified by microscopical examination of stained vaginal smears. Proestrus females were co-habitat with adult Wistar male at the ratio of 2:1 and mating was confirmed by presence of sperms in the vaginal smear. The day on which sperm cells were observed in the vaginal smear was considered as day zero of pregnancy, after which the female rats was separated from the male rat. Out of the six female rats exposed to male, five female rats whose vaginal smears were positive for sperm cells were confirmed pregnant by ultrasonography. This study concludes that the Field staining can be used as a simple, rapid and less expensive technique to confirm mating by vaginal exfoliative cytology in rats.

**Keywords:** Vaginal exfoliative cytology, staining method, estrous cycle, mating, rat

**Introduction**

Rats are non-seasonal polyestrus, spontaneous ovulators and puberty occurs at 37 to 67 days of age (Maeda *et al.*, 2000) [1]. From the onset of sexual maturity up to an age of 12 months, the estrous cycle length in female rat is 4 to 5 days; which is characterized by proestrus (12 h), estrus (9-15h), metestrus (21 h) and diestrus (57 h) (Lohmiller and swing, 2006) [2]. During this period, ovaries undergo a number of morphological, biochemical and physiological changes leading to the ovulation. There are many methods to identify the stages of estrous cycle viz. visual observation of external genitalia, histological examination of reproductive tract (Ajayi and Akhigbe, 2020) [3], vaginal wall impedance (Ramos *et al.*, 2001) [4], measuring of steroid level and vaginal cytology (Paccola *et al.*, 2013) [5]. However, determination of optimal mating time based on estrus observation is limited due to low performance of estrus especially at day time and electrical impedance requires costlier instruments. While, histological and steroid examinations are relatively take longer time period. Thus, an alternative and simple technique that can be easily used by researchers to characterize reproductive cycle as well as to identify the breeding time is vaginal cytology.

As rats are used extensively in various research areas including reproductive physiology, behavioural, toxicological, screening and treatment of various disease condition, transgenic and knockout technology, timed mating in rats are highly needed. Since rats are nocturnal animal, mating is difficult to judge and not always practical to observe the copulatory act (Hafez, 1970; Inglis, 1980) [6, 7]. Hence, confirmation of mating in the rat is therefore usually made by checking for the presence of spermatozoa in a vaginal smear or by visualization of the copulatory plug (Bennett and Vickery, 1970; Berthelot, 1981) [8, 9]. However the disadvantage of vaginal plug is either it may be deeply located in the vagina or it may dislodge and fall in to the bedding materials and therefore it is difficult to detect on vaginal inspection. The other possibilities to confirm mating is detection of sperms in the vaginal cytology. Numerous studies have been made of cytology of vaginal cells by means of Leishmans or Trichrome stains (Hartman, 1944) [10], crystal violet (Mclean *et al.*, 2012) [11], Papanicolaou stain (Cora *et al.*, 2015) [12] but most of the stains are expensive, time consuming and cumbersome to use. Hence, present study, describes a method of confirming mating in rats by presence of sperms in the vaginal smear using a simple, rapid and less expensive staining technique.

## Materials and Methods

### Animals

Six adult female and three male Wistar rats (*Rattus norvegicus*) weighing about 220-250g (8-9 weeks old) were obtained from the Department of Laboratory Animal Medicine (TANUVAS, Madhavaram, Chennai, Tamil Nadu, India). All the rats were housed under controlled temperature (24-28° C) and illumination (12 h light/12 h dark cycle). Maximum of 3 rats per cage were housed in a cages of laboratory rat with food (standard pelleted rat feed) and water were provided *ad libidum*. This experiment was approved by the Institutional Animal Ethics Committee.

### Vaginal Exfoliative Cytology

To determine the stages of the estrous cycle, vaginal smears were collected twice a day at the same time (morning and

evening) from all the animals for 10 consecutive days. A sterile cotton swab soaked in distilled water or physiological saline solution was gently introduced in to the vaginal orifice and rotated against the vaginal wall and taken out. It is then gently rolled from one end to the other end of a clean grease free glass slide. The slide is then air dried, fixed in 95-100% methanol for 1 minute and stained in field solutions of A and B (Fig. 1). The fixed smear is covered with diluted field B solution (1 in 4 in buffered water) immediately followed by addition of field A solution, mixed and left for 2-3 minutes (slight modification in timing to get good result). The slide is rinsed with clean water, air dried and observed under light microscope for assessing the stage of estrous cycle. The vaginal epithelial cells are classified as basal, intermediate, superficial intermediate, superficial, cornified as described by Nelson *et al.* (1982) [13].



**Fig 1:** Field stain A and and B

### Confirmation of mating time

Based on vaginal cytology, proestrus females were placed together with male at the ratio of one male: two females. After introduction of male, vaginal smears were collected from the female as described earlier. Mating was confirmed by presence of sperms in the vaginal smear. The day on which sperm cells were observed in the vaginal smear was considered as day zero of pregnancy, after which the female rats was separated from the male rat. On day 12 to 15 following mating, pregnancy diagnosis was done using ultrasonography (ALOKA Prosound).

### Results

The epithelial cell types present in vaginal smears during different stages of estrous cycle in rat is presented in table 1. In proestrus, vaginal smear showed predominant of basal, intermediate and few superficial intermediate cells (Fig. 2A).

As it proceeds towards estrus, cornified cells were seen in clumps or in sheets and superficial cells with disintegrated or pyknotic nucleus (Fig.2B). In metestrus, vaginal cytology revealed few keratinized cells and leucocytes with darkly pigmented polymorpho-nucleus (Fig.2D). While in diestrus, clusters of leukocytes were noticed along with few intermediate and superficial intermediate cells (Fig.2E). Though there is no clear demarcation between metestrus and diestrus stage, however in metestrus appearance of leukocytes and presence of few cornified and superficial cells of previous stage of estrus may help in differentiation.

Out of the six female rats exposed to male, five female rats whose vaginal smears were positive for sperm cells (Fig. 2C) were confirmed pregnant by ultrasonography. One female rat, where in sperm cells could not be identified in the vaginal cytology did not show any signs of pregnancy was found to be non pregnant.

**Table 1:** Epithelial cell types present in vaginal smears during different stages of estrous cycle in Rats

Cell Type Stages	Basal	Intermediate	Superficial Intermediate	Superficial	Anuclear/ Keratinized	Leukocytes
Proestrus	++	+++	+++	+/-	-	+/-
Estrus	-	-	+	++	+++	+/-
Metestrus	-	+	+	+	++	+++
Diestrus	+	+++	++	-	+/-	+++

**Note:** none (-); few (+); moderate (++); high(+++).

### Discussion

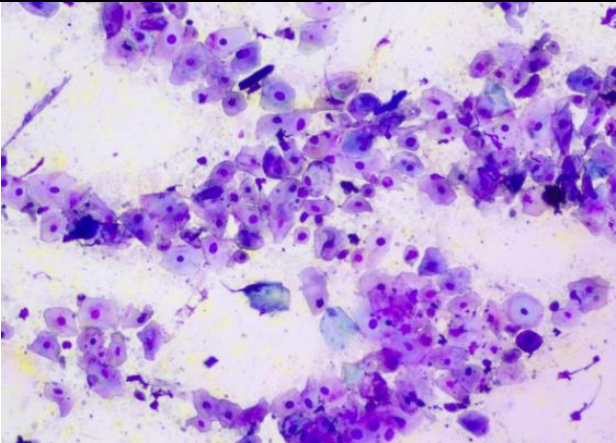
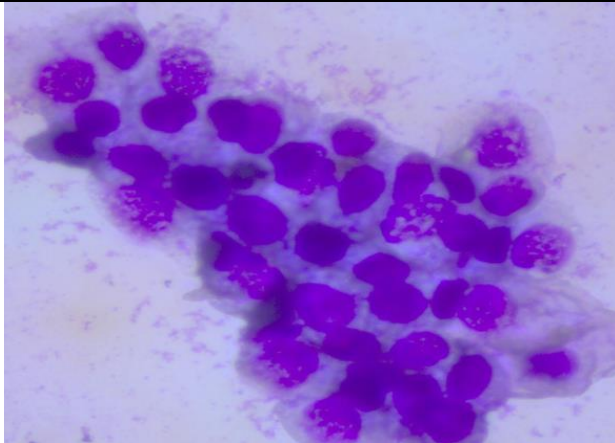
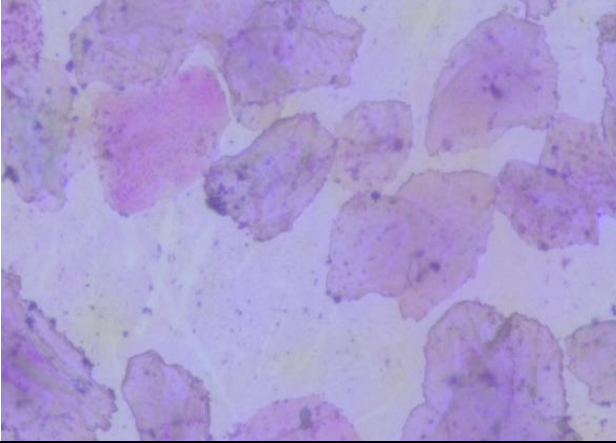
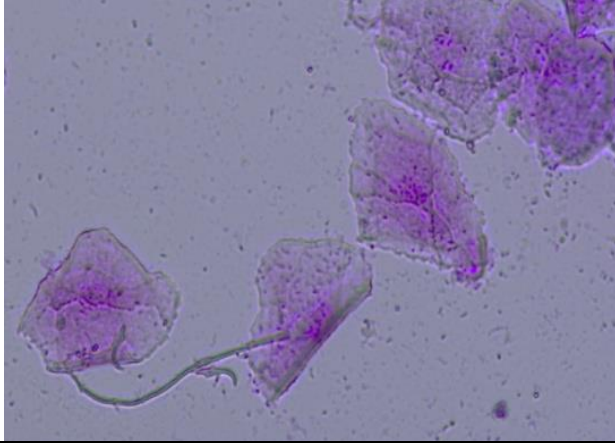
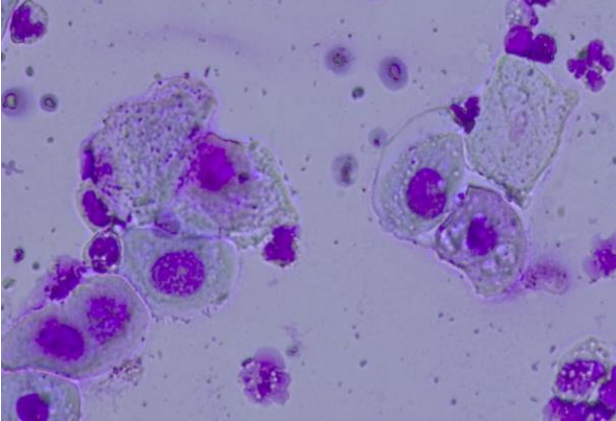
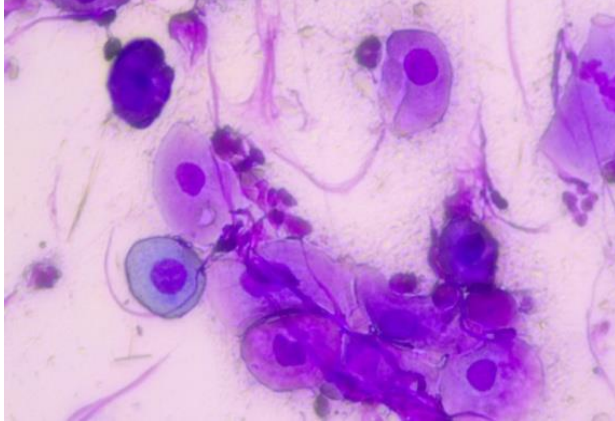
Vaginal smear is a delicate indicator of estrous cycle, which could also be used as a tool that represents the balance of estrogen and progesterone levels in the blood. The maturation

of vaginal epithelium is determined by the local action of the steroid hormones that promote changes in cell size and nucleus-cytoplasmic relation (Chappell *et al.*, 2000 and Martins *et al.*, 2005) [14, 15]. Steroid hormones also enhances

the exfoliation of vaginal mucosa and results in bulging of outermost layer of epithelium away from the vascular supply and easy to detach from the lumen, which results in exfoliation of dead cells called keratinized cells.

The collection of vaginal swabs for making the smears did not interfere with pregnancy as indicated by the fact that five out of six mated females became pregnant. This was in accordance with the report of Ochiogu *et al.*, (2006) [16]. Baker (1979) [17] also confirmed mating by vaginal smears and reported 90 to 94 percent correlation between sperm-

positive vaginal smears and pregnancy. The method of collection and preparation of vaginal smear is a noninvasive and simple procedure; however with proper training and expertise it can easily be employed in predicting mating time in rats. Thus, vaginal cytology may not only be used in normal cycle evaluation but also used to identify abnormal oestrous cycle, inflammatory condition of reproductive tract, false estrus (Klaas Post, 1985) [18] and other abnormal reproductive conditions in rat.

	
<p><b>Fig 2A:</b> Images showing Intermediate and Superficial Intermediate cells at Proestrus stage(10x)</p>	<p><b>Fig 2A:</b> Images showing predominant of Intermediate along with Basal cells at Proestrus stage (40x)</p>
	
<p><b>Fig 2B:</b> Images showing predominant of Cornified cells at Estrus stage (40x)</p>	<p><b>Fig 2C:</b> Images showing presence of Sperm head and tail along with Cornified cells indicating breeding occurred at Estus stage (40x)</p>
	
<p><b>Fig 2D:</b> Images showing Intermediate cells and few Cornified cells along with leucocytes at Metestrus stage (40x)</p>	<p><b>Fig 2E:</b> Images showing Intermediate cells and and Superficial Intermediate cells along with leucocytes at Diestrus stage (40x)</p>
<p><b>Fig 2(A-E):</b> Vaginal cytology stained with Field staining showing different stages of Estrous cycle in Female Rat</p>	

## Conclusion

Although there are many references regarding the vaginal cytology of the rat estrous cycle, the staining technique described in the present study is simple, rapid and less expensive to confirm mating in rats.

## Acknowledgment

The authors thank the Dean of Madras Veterinary College, Directorate of Clinics and Dr. P.Sridevi, Professor and Head (Rtd.) of Veterinary Gynaecology and Obstetrics department, TANUVAS for supporting and GOI for providing necessary financial assistance under the DBT-TANUVAS Canine Research Centre and Networks project on “Canine Contraception”.

## References

1. Maeda K, Ohkura S, Tsukamura H. Physiology of reproduction. In: Krinke GJ (Ed.). *The Laboratory Rat: Handbook of Experimental Animals*. London, UK: Academic Press. 2000, 145-176.
2. Lohmiller JJ, Swing SP. Reproduction and breeding. In: Suckow MA, Weisbroth SH, Franklin CL (Ed.). *The Laboratory Rat*. 2nd. ed. New York, NY: Academic Press, 2006, 157-163.
3. Ajayi AF, Akhigbe RE. Staging of the estrous cycle and induction of estrus in experimental rodents: an update, *Fertility Research and Practice*. 2020; 6(5):1-15.
4. Ramos SD, Lee JM, Peuler JD. An inexpensive meter to measure differences in electrical resistance in the rat vagina during the ovarian cycle, *J Appl Physiol*. 2001; 91:667-70.
5. Paccola CC, Resende CG, Stumpp T, Miraglia SM, Cipriano I. The rat estrous cycle revisited: a quantitative and qualitative analysis, *Anim. Reprod*. 2013; 10(4):677-683.
6. Hafez ESE. *Reproduction and Breeding Techniques for Laboratory Animals*. Lea and Febiger, Philadelphia, 1970.
7. Inglis JK. Reproduction, breeding and heredity. In: Inglis J K (Ed.). *Introduction to Laboratory Animal Science and Technology*. Pergamon Press, Oxford, 1980, 156-234.
8. Bennett JP, Vickery BH. Rats and mice – copulation and mating behaviour. In: Hafez ESE (Ed.). *Reproduction and Breeding Techniques for Laboratory Animals*. Lea and Febiger, Philadelphia. 1970; 302-303.
9. Berthelot JY. Mating methods to produce accurate timed pregnancy in rats, *Laboratory Animal Science*. 1981; 31:180-186.
10. Hartman CG. Some new observations on the vaginal smear of the rat, *Yale J Biol Med*. 1944; 17:99-111.
11. McLean AC, Nicolas Valenzuela, Stephen Fai, Steffany AL, Bennett. Performing Vaginal Lavage, Crystal Violet Staining, and Vaginal Cytological, *Journal of Visualized Experiments*. 2012; 67:1-6.
12. Cora MC, Kooistra L, Travlos G. Vaginal Cytology of the Laboratory Rat and Mouse: Review and Criteria for the Staging of the Estrous Cycle Using Stained Vaginal Smears, *Toxicologic Pathology*. 2015; XX:1-18.
13. Nelson JF, Felicio LS, Randall PK, Sims C, Finch CE. A longitudinal study of estrous cyclicity in aging C57BL/6J Mice: I. cycle frequency, length and vaginal cytology, *Biol Reprod*. 1982; 27:327-39.
14. Chappell PE, Levine JE. Stimulation of Gonadotropin-Releasing hormones Surges by Estrogen. I. Role of

Hypothalamic Progesterone Receptors, *Endocrinology*. 2000; 141:1477-85.

15. Martins RR, Lemos Pereira NM, Araujo Silva TM. Liquid-base cytology: a new method for oestral cycle study in wistar's rats, *Acta Cir. Bras*. 2005; 20:1-3.
16. Ochiogu IS, Uchendu CN, Ihedioha JI. A new and simple method of confirmatory detection of mating in albino rats (*Rattus norvegicus*), *Animal Research International*. 2006; 3(3):527-530.
17. Baker DEJ. Reproduction and breeding. In: Baker HJ, Lindsey JR, Weisbroth SH. (Ed.). *The Laboratory Rat*, first ed., Academic Press, New York. 1979; 1:153-168.
18. Klaas Post. Canine vaginal cytology during the estrous cycle, *Can Vet J*. 1985; 26:101-104.