



E-ISSN: 2320-7078

P-ISSN: 2349-6800

[www.entomoljournal.com](http://www.entomoljournal.com)

JEZS 2020; 8(5): 1953-1955

© 2020 JEZS

Received: 26-06-2020

Accepted: 28-08-2020

**Satbir Sharma**

Department of Veterinary  
Surgery and Radiology, College  
of Veterinary Sciences,  
Lala Lajpat Rai University of  
Veterinary and Animal Sciences,  
Hisar, Haryana, India

**Dishant Saini**

Department of Veterinary  
Surgery and Radiology, College  
of Veterinary Sciences,  
Lala Lajpat Rai University of  
Veterinary and Animal Sciences,  
Hisar, Haryana, India

**Neeraj Arora**

Department of Veterinary  
Surgery and Radiology, College  
of Veterinary Sciences,  
Lala Lajpat Rai University of  
Veterinary and Animal Sciences,  
Hisar, Haryana, India

**Deepak Kumar Tiwari**

Department of Veterinary  
Surgery and Radiology, College  
of Veterinary Sciences,  
Lala Lajpat Rai University of  
Veterinary and Animal Sciences,  
Hisar, Haryana, India

**Akshay Tikoo**

Department of Veterinary  
Surgery and Radiology, College  
of Veterinary Sciences,  
Lala Lajpat Rai University of  
Veterinary and Animal Sciences,  
Hisar, Haryana, India

**Bijender Singh**

Department of Veterinary  
Surgery and Radiology, College  
of Veterinary Sciences,  
Lala Lajpat Rai University of  
Veterinary and Animal Sciences,  
Hisar, Haryana, India

**Corresponding Author:****Deepak Kumar Tiwari**

Department of Veterinary  
Surgery and Radiology, College  
of Veterinary Sciences,  
Lala Lajpat Rai University of  
Veterinary and Animal Sciences,  
Hisar, Haryana, India

## Surgical management of ocular setariosis in stallion

**Satbir Sharma, Dishant Saini, Neeraj Arora, Deepak Kumar Tiwari, Akshay Tikoo and Bijender Singh**

**Abstract**

Equine ocular setariosis is an important cause of corneal opacity. A stallion was presented to the department with a history of lacrymation, photophobia and progressive corneal cloudiness on the right eye since last ten days. Clinical examination revealed swirling movement of a white thread like worm in the anterior chamber of the affected eye. A slightly modified needling technique using U-shape hook was used for the removal of eye worm under general anaesthesia. Lacrymation was reduced to normal within seven days and corneal opacity was completely cleared on 14<sup>th</sup> post-operative day. Animal showed uneventfully recovery and regained complete clear vision on 15<sup>th</sup> post-operative day.

**Keywords:** Equine, Eye, Ocular, Setariosis, Setaria, Worm

**Introduction**

Equine ocular setariosis is an important cause of corneal opacity and commonly by *Setaria digitate*, *Setaria equina* and *Thelazia lacrymalis* [1, 2, 3, 4]. The usual predilection site of adult setaria worms is in the peritoneal cavity. Occasionally they can get into the central nervous system or the eye [5]. Equines are more prone for ocular worm [6, 7]. The infected animals usually display signs of lacrimation, photophobia, corneal opacity, conjunctivitis and even loss of vision [8, 9]. The serrated cuticle of the worm and lashing movements within the anterior chamber of the eye cause severe trauma and inflammation of the cornea and results into blindness [10]. The dead worm possibly liberates toxins into the anterior chamber, which may be lethal to the endothelium and result into corneal oedema. It may lead to devastating sequel like synechia, cataract, and retinal detachment [11]. Though, the involvement of the eye is commonly unilateral but bilateral occurrence has also been reported [12, 13]. The best treatment of ocular setariasis is the surgical removal of the parasite that can be performed under general anaesthesia along with regional nerve blocks.

**Case History and Management**

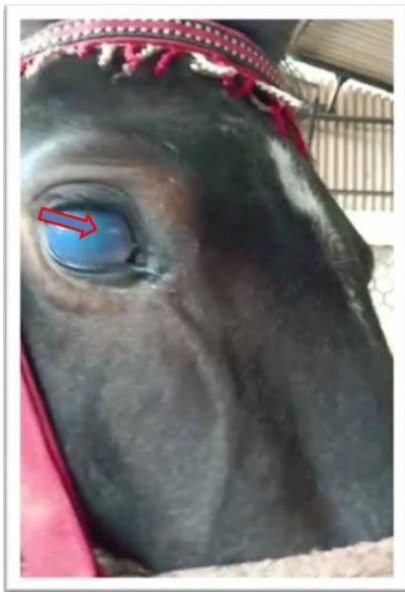
A 10-year-old stallion was presented to Veterinary Clinical Complex, Hisar with a history of corneal opacity, lacrimation, photophobia and impaired vision in the right eye since last ten days. Clinical examination of the affected eye revealed free swirling movement of white thread like worm in anterior chamber (Fig 1). It was clearly visible and diagnosed as eye worm based on the location in the anterior chamber of the eye in aberrant host. Blood sample was collected for haematological and biochemical parameters analysis which revealed normal physiological picture except increase in eosinophils. The stallion was admitted to the department for surgical management of eye worm. Preoperatively, non-steroidal anti-inflammatory agent (0.3% Flurbiprofen) was instilled and antibiotic (ofloxacin) ointment was applied on the cornea half an hour prior to corneal manipulation. The horse was sedated with intravenous administration of xylazine hydrochloride at the dose of 1.1 mg/kg b.wt. along with butarphanol at the dose rate of 0.01 mg/kg b.wt. General anaesthesia was induced and maintained by intravenous administration of ketamine hydrochloride at the dose rate of 2 mg/kg b.wt. and diazepam at the dose rate of 0.1 mg/kg b.wt. along with infiltration of 2% lignocaine hydrochloride (2ml) in auriculopalpebral and supraorbital nerve area to stabilise the eyeball and eyelids, respectively. The animal was restrained by side line method and positioned in left lateral recumbency on soft bedding. The periocular skin of the affected eye was prepared for surgery with aseptic technique which include clipping of hairs and scrubbing with 4% chlorhexidine gluconate

solution. Eyeball was held and fixed in a stable position with the paper tape and hand so as to expose the cornea. Needle aspiration was performed at 6 O' clock position, approximately 1mm from the limbus bordering the clear cornea. To remove the parasite an incision on the limbus at 6 O'clock position with No. 11 surgical blade was made and a modified U-shaped hook made by bending 24-gauge needle tip was inserted inside the anterior chamber to remove the parasite (Fig 2). Due to the aqueous humour pressure, the eye worm was trapped inside the hook. Hook was withdrawn carrying the eye worm in its arm and eye worm was kept in normal saline (Fig 3).

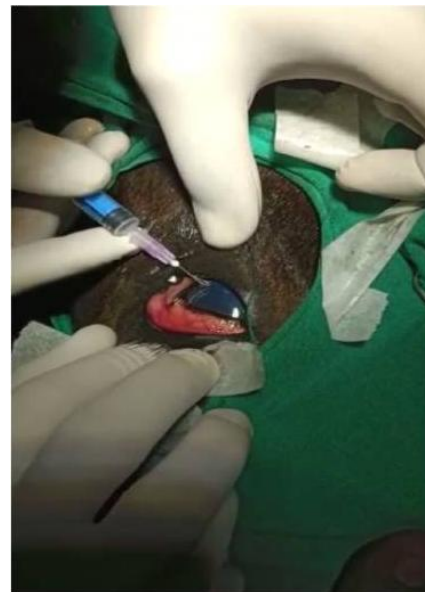
After removal of the parasite, the affected eye was thoroughly flushed with normal saline. Finally, air was injected to reform the anterior chamber. Aqueous leakage was minimal as the incision was very small. Post-operative management consisted of topical administration of non-steroidal anti-inflammatory agent (0.3% Flurbiprofen) and ofloxacin eye ointment thrice daily for two weeks. Dexamethasone eye drop were also prescribed to manage corneal opacity. Parental administration of ceftriaxone at the dose rate of 10mg/kg body weight and chlorpheniramine maleate at the dose of 0.5mg/kg body weight intramuscularly, once daily for five days. Owner was advised to cover the eye with a piece of clean cloth to avoid direct sunlight falling onto the affected

eye. Epiphora was reduced to normal lacrymation within seven days and corneal opacity was completely cleared on 14<sup>th</sup> post-operative day.


The adult *Setaria* species parasite is usually found in the peritoneal cavity of equines and normally considered as harmless to the host [14]. Incidence of ocular setariosis in equines has been reported by various authors in relation with clinical signs like lacrimation, conjunctivitis, cloudiness of cornea, ultimately leading to complete corneal opacity. It is considered that the erratic movement of the worm within the eye cause severe irritation to the corneal endothelium leading to corneal oedema (steamy eye), kerato-uveitis and even blindness [12, 15]. Needle aspiration technique (i.e application of 16-gauge needle connected with 10 ml syringe) through the limbus into the anterior chamber is simple, easy and quick method without complication [16]. However, in the present communication 24-gauge needle was used to make U-shape hook to remove the eye worm. The choice of ventral incision is also preferred for additional protection of wound by nictitating membrane, which is in agreement with other authors [9]. To minimize the possibility of aqueous leakage, the stab incision should be made in a closed valve manner by using an angled knife [17]. Animal recovered uneventfully and regained complete clear vision on 15<sup>th</sup> post-operative day onwards.



**Fig 1:** White thread like worm moving in the anterior chamber of affected eye (Red arrow) with marked corneal opacity



**Fig 2:** Insertion of modified U-shaped hook made of 24-gauge needle tip inside the aqueous chamber to remove the parasite



**Fig 3:** Eye worm (red circle) kept with normal saline in a syringe

### Conclusion

Surgical management of ocular setariosis in stallion with modified needling technique using U-shape hook was found to be effective and reliable for the removal of eye worm with good prognosis.

### Acknowledgement

The authors are highly thankful to the Department of Veterinary Surgery and Radiology and Department of Veterinary Clinical Complex, College of Veterinary Sciences, Lala Lajpat Rai University of Veterinary and Animal Sciences, Hisar, Haryana, for providing necessary facilities.

**Conflict of Interest Declaration:** Authors disclose no-conflict of interest.

### References

1. Sathu S. Intraocular parasites in horses: A report of five cases. *Indian Veterinary Journal*. 1974; 5:225.
2. Ladoucer CA, Kazacos KR. *Thelazia lacrimalis* in horses in India. *Journal of American Veterinary Medical Association*. 1981; 178:301-302.

3. Parrah JD, Buchoo BA, Moulvi BA. Ocular filariasis in equines: A study of 9 cases. *Centaur*. 2004; 4:70-71.
4. Sellon CD, Long M. *Equine Infectious Diseases*. 2<sup>nd</sup> edn. Science Direct Publication, St. Louis, MI, 2013.
5. Yadav A, Kumar A, Bhadwal MS, Khajuria JK, Gupta A. Ocular setariosis in horses: A case study. *Journal of Veterinary Parasitology*. 2006; 20:1-10.
6. Jayakumar K, Dharmaceelan S, Rajendran N, Senthilkumar S, Kathirvel S, Nagarajan L *et al*. Ocular Setariasis in a Pony. *Indian Veterinary Journal*. 2012; 89:64-66.
7. Radwan AM, Ahmed NE, Elakabawy LM, Ramadan MY, Elmadaawy RS. Prevalence and pathogenesis of some filarial nematodes infecting donkeys in Egypt. *Veterinary World*. 2016; 9:888-892.
8. Basak SK, Hazra TK, Bhattacharya D. Persistent corneal edema secondary to presumed dead adult filarial worm in the anterior chamber. *Indian Journal of Ophthalmology*. 2007; 55:67-69.
9. Patil DB, Parikh PV, Joy N, Jhala SK, Dar M, Tiwari DK *et al*. Equine Eye Worm: A Review of 50 cases. *Indian Journal of Veterinary Surgery*. 2012; 33:61-62.
10. Jaiswal S, Singh SU, Singh B, Singh HN. Ocular setariosis in a horse. *Intas Polivet*. 2006; 7:67-68.
11. Paglia DT, Miller PE, Dubielzig RR. James Wardrop and equine recurrent uveitis. *Archiv of Ophthalmology*. 2004; 122:1218-1223.
12. Shin S, Cho K, Wee SH. Ocular infection of cattle with *Setaria digitata*. *Journal of Veterinary Medical Science*. 2002; 64:7-10.
13. Buchoo BA, Pandit BA, Shahardar RA, Parrah JD, Darzi, MM. Surgical management and prevalence of ocular filariasis in equines. *Indian Veterinary Journal*. 2005; 82:81-82.
14. Mritunjay K, Monsang SW, Pawde AM, Singh SK, Madhu DN, Zama MMS *et al*. Post-surgical healing effect of placentrex in equine (*Equus caballus*) ocular setariasis: A review of 22 cases. *Indian Field Veterinary Journal*. 2011; 6:71-73
15. Ansari MM, Buchoo BA. Surgical technique for removal of intraocular parasite in horse. *Intas Polivet*. 2005; 2:256.
16. Singh H, Chaudhuri PC, Kumar A. Paracentesis oculi: a preferred technique for removal of intraocular parasites in horses. *Indian Veterinary Journal*. 1976; 53:467-468.
17. Kalpravidh M, Bramasa A, Kalpravidh C. Surgical removals of intraocular parasites from the anterior chambers of the horse eyes. *Thailand Journal Veterinary Medicine*. 1992; 22:13-20.