



E-ISSN: 2320-7078

P-ISSN: 2349-6800

www.entomoljournal.com

JEZS 2020; 8(4): 995-996

© 2020 JEZS

Received: 13-05-2020

Accepted: 15-06-2020

Gautam Bordoloi

Department of Veterinary Parasitology,
Lakhimpur College of Veterinary Science
Assam Agricultural University, Joyhing,
North Lakhimpur, Assam, India

Prasanta Kumar Boro

Department of Veterinary Medicine,
Lakhimpur College of Veterinary Science
Assam Agricultural University, Joyhing,
North Lakhimpur, Assam, India

Sanjib Khargharia

Department of Pharmacology & Toxicology,
Lakhimpur College of Veterinary Science
Assam Agricultural University, Joyhing,
North Lakhimpur, Assam, India

L Sanathoi Khuman

Department of Extension Education,
Lakhimpur College of Veterinary Science
Assam Agricultural University, Joyhing,
North Lakhimpur, Assam, India

Karuna Saikia

Department of Livestock Farm Complex,
Lakhimpur College of Veterinary Science
Assam Agricultural University, Joyhing,
North Lakhimpur, Assam, India

Kandarpa Boruah

Department of Livestock Production &
Management, Lakhimpur College of
Veterinary Science Assam Agricultural
University, Joyhing, North Lakhimpur,
Assam, India

Prasanta Chabukdhara

Department of Physiology & Biochemistry,
Lakhimpur College of Veterinary Science
Assam Agricultural University, Joyhing,
North Lakhimpur, Assam, India

Dwipjyoti Mahanta

Department of Veterinary Anatomy and
Histology, Lakhimpur College of Veterinary
Science Assam Agricultural University,
Joyhing, North Lakhimpur, Assam, India

Manoj Kumar Kaita

Department of ARGO, Lakhimpur College
of Veterinary Science Assam Agricultural
University, Joyhing, North Lakhimpur,
Assam, India

Aditya Baruah

Department of Veterinary Public Health &
Epidemiology, Lakhimpur College of
Veterinary Science Assam Agricultural
University, Joyhing, North Lakhimpur,
Assam, India

Mridupavan Baishya

Department of Veterinary Surgery and
Radiology, Lakhimpur College of Veterinary
Science Assam Agricultural University,
Joyhing, North Lakhimpur, Assam, India

Corresponding Author:

Gautam Bordoloi

Department of Veterinary Parasitology,
Lakhimpur College of Veterinary Science
Assam Agricultural University, Joyhing,
North Lakhimpur, Assam, India

Oriental theileriosis in Lakhimi cattle of Assam in the Eastern Himalayan foothills bordering the states of Assam and Arunachal Pradesh in India: A case report

Gautam Bordoloi, Prasanta Kumar Boro, Sanjib Khargharia, L Sanathoi Khuman, Karuna Saikia, Kandarpa Boruah, Prasanta Chabukdhara, Dwipjyoti Mahanta, Manoj Kumar Kaita, Aditya Baruah and Mridupavan Baishya

Abstract

Theileriosis in cattle is a very important disease that causes economic loss through abortion and even death of the dairy cattle. Oriental theileriosis caused by *Theileria orientalis* is a disease newly reported from cattle of Assam, India. Two numbers of newly registered Lakhimi cattle breed from Assam were reported with high fever, swollen pre-scapular lymph nodes and mild anaemia. Laboratory diagnosis revealed presence of intraerythrocytic piroplasms of *Theileria orientalis*. Previously no published document was found regarding the occurrence of *Theileria orientalis* in Lakhimi cattle of Assam from the area of the present communication. Hence, this may be considered as the first report of *Theileria orientalis* in the Lakhimi cattle from Eastern Himalayan foothills bordering the states of Assam and Arunachal Pradesh.

Keywords: Oriental theileriosis, Lakhimi cattle, Eastern Himalayan foothills, Arunachal Pradesh, Assam

Introduction

Theileriosis in cattle is a very important tick borne haemoprotozoan disease that results in decreased production and even sometimes death of the animal. Oriental theileriosis, caused by *Theileria orientalis*, is transmitted by ixodid ticks. This parasite has emerged as a pathogenic species in the recent past, some virulent strains of which can cause fatal disease [1], which was previously regarded as a non pathogenic species or may cause a mild or benign disease [2]. Theileriosis is predominant in countries of tropics and subtropics [3]. The prevalence of this disease is directly dependent upon the presence of its tick vector *Haemaphysalis* and *Boophilus* spp. [1, 4, 5]. In Assam, *Theileria orientalis* was proven to be transmitted by *Rhipicephalus (Boophilus) microplus* through transovarian route [6]. Diseased animal may show signs like fever, anaemia, jaundice and abortion and even death of the animal [7, 8]. These cause economic loss to the livestock owner. Though the animal may recover but it will remain as a source of infection for life [4].

Case history

Lakhimpur district of Assam is located in the foothills of Arunachal Pradesh in the north bank plain zone of river Brahmaputra. The climate of this area is hot and humid which favours the propagation of tick vectors. Two numbers of newly registered Lakhimi breed of cattle of Assam were brought to the Veterinary Clinical Complex of Lakhimpur College of Veterinary Science, Assam Agricultural University, Joyhing, North Lakhimpur with symptoms like high fever, swollen pre-scapular lymph nodes and mild anaemia. The animals were suspected to have suffered from some haemoprotozoan diseases and blood from jugular vein and lymph node aspiration fluid of the swollen lymph nodes were collected for confirmatory diagnosis in the laboratory.

Results and Discussion

The blood and lymph smears were made and stained with Giemsa stain following standard

protocol. The blood smears revealed the presence of rod shaped intraerythrocytic stage (piroplasms) of *Theileria orientalis* in many of the RBC's in both the cases (Fig. 1). Although no lymphocytic (schizont) stage was detected in blood or lymph smears.

Report of theileriosis from Assam and other North Eastern states of India are scanty. Previously it was reported from two adjoining states of Assam viz., Tripura and West Bengal [9, 10]. Although *Theileria orientalis* has been reported in Assam [6], this is the first instance where *Theileria orientalis* has been found in Lakhimi cattle in the foothills of Eastern Himalayan range bordering the states of Arunachal Pradesh and Assam. Detection of *Theileria* intraerythrocytic stages in the present report may be the result of changes in the distribution pattern of its tick vectors which helped them to spread in the newer areas.

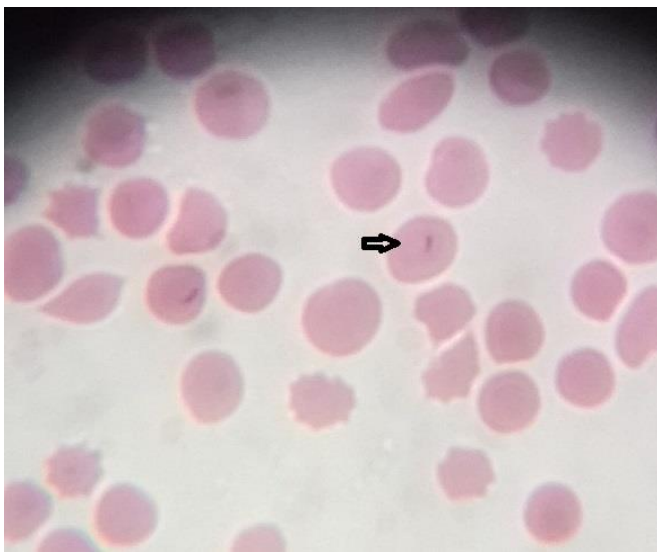


Fig 1: Intraerythrocytic stage of *Theileria orientalis*

Conclusion

The present communication is intended to report the presence of *Theileria orientalis* in Lakhimi cattle of Assam, and their role as reservoir of the organism in the dissemination of the disease / infection to the high yielding cross bred cows in these areas which may lead to severe economic loss in future. This may be considered as the first report of oriental theileriosis in Lakhimi cattle from the Himalayan foothills bordering the states of Assam and Arunachal Pradesh as no published reports were found from any previous worker in this area.

Acknowledgements

The author acknowledges Associate Dean, LCVSc., AAU, Joyhing, North Lakhimpur for providing all the facilities required for completion of the present work.

References

1. Aparna M, Ravindran R, Vimalkumar MB, Lakshmanan B, Rameshkumar P, Ajith Kumar KG *et al.* Molecular characterization of *Theileria orientalis* causing fatal infection in crossbred adult bovines of South India. *Parasitology International*. 2011; 60:524-529.
2. Constable DP, Hinchcliff WK, Done HS, Grunberg W. *Veterinary Medicine: A Textbook of the Diseases of Cattle, Horses, Sheep, Pigs, and Goats* (11th Ed). Elsevier Ltd., Missouri, 2017, 2144.

3. Uilenberg G. International collaborative research: significance of tick-borne haemoparasitic diseases to world animal health. *Veterinary Parasitology*. 1995; 57:19-41.
4. Watts JG, Playford MC, Hickey KL. *Theileria orientalis*: a review. *The New Zealand Veterinary Journal*. 2016; 64:3-9.
5. Chae JS, Allsopp BA, Waghela SD, Park JH, Kakuda T, Sugimoto C *et al.* A study of the systematics of *Theileria* spp. based upon small-subunit ribosomal RNA gene sequences. *Parasitology Research*. 1999; 85(11):877-83.
6. Kakati P, Sarmah PC, Ray D, Bhattacharjee K, Sharma RK, Barkalita LM *et al.* Emergence of oriental theileriosis in cattle and its transmission through *Rhipicephalus (Boophilus) microplus* in Assam, India. *Veterinary World*. 2015; 8(9):1099-1104.
7. McFadden AM, Rawdon TG, Meyer J, Makin J, Morley CM, Clough RR *et al.* An outbreak of haemolytic anaemia associated with infection of *Theileria orientalis* in naive cattle. *The New Zealand Veterinary Journal*. 2011; 59(2):79-85.
8. Eamens GJ, Bailey G, Jenkins C, Gonsalves JR. Significance of *Theileria orientalis* types in individual affected beef herds in New South Wales based on clinical, smear and PCR findings. *Veterinary Parasitology*. 2013; 196(1, 2):96-105.
9. Das SS. Prevalence of haemoprotozoan parasites in domestic animals in Tripura (India). *Journal of Parasitology and Applied Animal Biology*. 1993; 2:71-74.
10. Das G, Ray D. PCR based detection of *Theileria annulata* infection in ticks collected from cattle of West Bengal (India). *Journal Veterinary Parasitology*. 2003; 17:11-14.