



E-ISSN: 2320-7078

P-ISSN: 2349-6800

www.entomoljournal.com

JEZS 2020; 8(3): 471-473

© 2020 JEZS

Received: 28-03-2020

Accepted: 30-04-2020

M Lakshmi Namratha

PhD Scholar, Department of
Veterinary Pathology, C.V.Sc.,
P.V.N.R.T.V.U, Hyderabad,
Telangana, India

Y Ravi Kumar

Assistant Professor, Department
of Veterinary Pathology, C.V.Sc.,
P.V.N.R.T.V.U, Hyderabad,
Telangana, India

M Lakshman

Professor and Head, Department
of Veterinary Pathology, C.V.Sc.,
P.V.N.R.T.V.U, Hyderabad,
Telangana, India

Corresponding Author:

Y Ravi Kumar

Assistant Professor, Department
of Veterinary Pathology, C.V.Sc.,
P.V.N.R.T.V.U, Hyderabad,
Telangana, India

Egg yolk peritonitis in a black swan: A case report

M Lakshmi Namratha, Y Ravi Kumar and M Lakshman

Abstract

Egg yolk peritonitis, sometimes referred as egg peritonitis and is a common condition seen in poultry, from the point of lay onwards. A black swan from a private farm was presented for postmortem examination to the Department of Veterinary Pathology, College of Veterinary Science, Hyderabad. History revealed anorexia, pale comb, reluctance to move, poor feather condition, diarrhea, weakness and death. Egg peritonitis was diagnosed based on gross necropsy findings and bacterial culture test. Necropsy examination of affected swan revealed the presence of amorphous or inspissated yolk material in the abdominal cavity with inflammatory changes in the ovary, oviduct and intestine. The *Escherichia coli* organisms were identified based on lactose fermenting pink colored round, smooth and glistening colonies on MacConkey's agar and black metallic sheen colonies on eosin methylene blue agar.

Keywords: Egg yolk peritonitis, necropsy examination, bacterial culture test, *Escherichia coli*

Introduction

Egg peritonitis is described as a reproductive disorder in poultry which include peritonitis, salpingitis and impaction of oviduct accompanied by cannibalism and vent pecking. It can occur as a severe flock problem and when it does it is usually associated with poor management [1]. Multiple etiologic factors have been ascribed to cause egg peritonitis, however, *Escherichia coli* is often incriminated as one of the major etiologic agents of egg peritonitis [2]. Egg yolk peritonitis is the inflammatory reaction of peritoneum caused by the presence of yolk material in the coelomic cavity. Yolk material by itself induces a mild inflammatory response and may be reabsorbed by the peritoneum. Since yolk is an excellent growth medium for bacteria, peritonitis may result from secondary bacterial infection leading to secondary ascites and organ inflammation causing morbidity, mortality and reduced egg production in the affected flocks [3, 4]. Antibiotic treatment of peritonitis caused by *E. coli* infections is usually ineffective. Management of body weight and uniformity, reproductive development (ovary follicle growth and maturation), and drinking water sanitation are the best preventive strategies.

The current paper deals with a case of egg peritonitis in a black swan.

Materials and Methods

A black swan from a private farm was presented for postmortem examination to the Department of Veterinary Pathology, College of Veterinary Science, Hyderabad.

History: Information regarding breed and strain, flock strength, method of rearing, vaccination schedule, source of feed and water, percentage of production, production drop and mortality were collected. History of the bird with respect to the clinical signs were noted.

Necropsy examination: The carcass was surface disinfected and necropsy was performed as per approved procedure [5] and thoroughly examined for gross pathological changes. Peritoneum was examined for its color, consistency, adhesion and nature of its exudate. Oviduct was removed and opened along its longitudinal axis for examination of internal contents and mucosal surface.

Bacterial cultural examination: Oviduct (infundibulum, magnum and uterus) and cloacal swabs were collected for screening of bacterial agents onto MacConkey agar and eosin

methylene blue agar (EMBA). Bacterial isolates were identified on the basis of their morphology and growth characteristics.

Results and Discussion

History revealed anorexia, pale comb, reluctance to move, poor feather condition, diarrhea, weakness and death. Upon necropsy, the condition of the carcass was fair and the pectoral muscles were red in appearance. Ruptured ovarian follicles and presence of amorphous yolk material in the peritoneal cavity were predominant (Fig.1). The yolk material was found attached to the surface of ova and the serous surface of the intestines and oviduct through strands (Fig. 2 and 3). Oviduct serosal blood vessels were congested and the mucosa revealed albuminous exudate with moderate congestion of its folds. Intestine showed mucus exudate, congestion of mucosa and adhesions (Fig. 3). Swabs from the oviduct and cloaca revealed small pink colonies of *E.coli* on EMB with green metallic sheen (Fig. 4). Similar lesions were also reported in hens by previous authors [7].

After producing the ova (yolks), they are passed to the infundibulum (oviduct) which, in normal egg production, will catch the yolks and transport them through the rest of the reproductive tract until they are eventually expelled as fully-formed eggs. However, when a bird is suffering from egg peritonitis, the yolk is not caught by the infundibulum, but is instead released into the coelomic cavity, where it provides the perfect growth medium for bacteria, with *E. coli* being most commonly isolated from affected birds. Once the infection has become established, it will infiltrate throughout the coelom and cause a widespread peritonitis. Swollen abdomen is usually noticed in hens with egg peritonitis which is due to the infection within the coelom causing fibrin deposition and fluid accumulation. It is believed that pathogenic *E. coli* from the normal intestinal microflora are the source of infection for the oviduct and ultimately, the peritoneal cavity when the intestinal barriers are damaged [4].

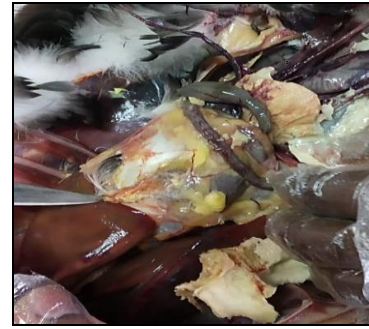

Fig 1: Presence of amorphous yolk material in the peritoneal cavity

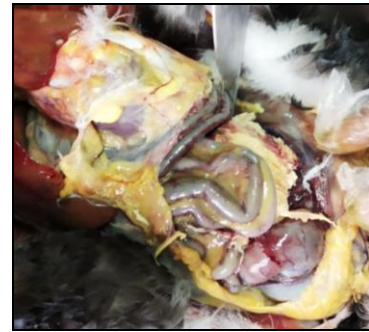


Fig 2: Yolk mass adhered to the intestines in the form of strands

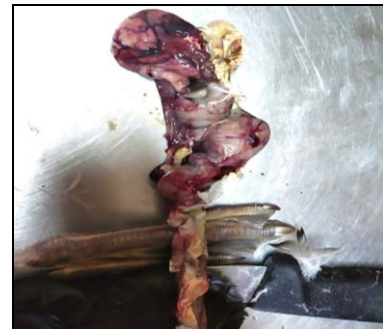

Fig 3: Adhesions in the intestines due to precipitated yolk mass

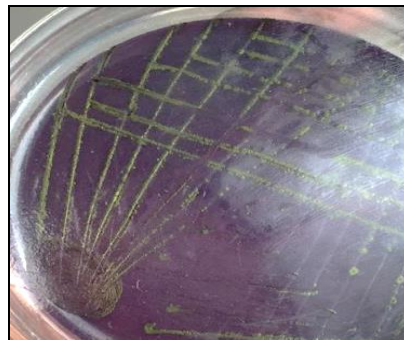


Fig 4: Small colonies of *E. coli* on EMB with green metallic sheen

Conclusion

Based on history and gross necropsy findings, it can be concluded that the death of the swan was due to egg yolk peritonitis caused by *E. coli* confirmed by cultural examination which may be as a result of damage to the intestinal barriers.

Acknowledgment

We thankfully recognize the accessibility of the necessary facilities provided by the Associate Dean, College of Veterinary Science, Rajendranagar for the smooth conduct of clinical research.

References

1. Jordan FTW. Poultry diseases. 3rd ed. Bailliere Tindall, London; 1990; 364:34-40.
2. Hofstad M, John Barnes H, Calnek BW, Reid HM, Yoder JR. Diseases of poultry. 8th ed. Iowa State University Press, Ames, Iowa, USA, 1984.
3. Zanella A, Alborali GL, Bardotti M, Candotti P, Guadagnini PF, Anna Martino P *et al*. Severe Escherichia coli O111 septicaemia and polyserositis in hens at the start of lay. Avian Pathology. 2000; 29(4):311-317.
4. Barnes HJ, Nolan LK, Vaillancourt JP. Colibacillosis. In: Saif YM, Fadly AM, Glisson JR, Mc Dougald LR,

- Swayne DE, Nolan LK, editors. Diseases of poultry. 12th ed. Iowa: Iowa State University Press; 2008, 691-738.
5. Chauhan HVS, Roy S. Poultry disease diagnosis and treatment. 3rd ed. New Delhi: New Age International (P) Limited Publication; 2007, 203-208.
 6. Quinn PJ, Markey BK, Leonard FC, Fitzpatrick ES, Fanning S, Hartigan PJ. Veterinary microbiology and microbial disease. 2nd ed. USA: John Wiley & Sons; 2011, 263-286.
 7. Srinivasan P, Balasubramaniam GA, Murthy TR, Balachandran P. Bacteriological and pathological studies of egg peritonitis in commercial layer chicken in Namakkal area. Asian Pacific journal of tropical biomedicine. 2013; 3(12):988-94.