



E-ISSN: 2320-7078

P-ISSN: 2349-6800

JEZS 2019; 7(4): 777-779

© 2019 JEZS

Received: 01-05-2019

Accepted: 03-06-2019

Akash

PG Scholar, U.P. Pt. Deen Dayal Upadhyay Pashu Chikitsa Vigyan, Vishwavidyalaya Evam Go-Ansundhan Sansthan, Mathura, Uttar Pradesh, India

G Kumar

Assistant Professor, U.P. Pt. Deen Dayal Upadhyay Pashu Chikitsa Vigyan, Vishwavidyalaya Evam Go-Ansundhan Sansthan, Mathura, Uttar Pradesh, India

RP Pandey

Head of the Department, Department of Veterinary Surgery & Radiology, U.P. Pt. Deen Dayal Upadhyay Pashu Chikitsa Vigyan, Vishwavidyalaya Evam Go-Ansundhan Sansthan, Mathura, Uttar Pradesh, India

Correspondence

Akash

PG Scholar, U.P. Pt. Deen Dayal Upadhyay Pashu Chikitsa Vigyan, Vishwavidyalaya Evam Go-Ansundhan Sansthan, Mathura, Uttar Pradesh, India

Standardization of ultrasonography examination protocol of adrenal glands in healthy dogs

Akash, G Kumar and RP Pandey

Abstract

The present study was undertaken in dogs to standardize Ultrasonography examination protocol of adrenal glands in apparently healthy dogs. The animals were divided into three groups of six animals each: group I (0 to 9 months), group II (> 9 months up to 6 yr) and group III (>6 yr). Ultrasonographic examination was done in lateral recumbency in all the examined dogs. Ultrasonographic scans of adrenal glands were recorded in sagittal plane. The adrenal glands were scanned by placing the transducer in the sub-costal area (immediately behind the last rib) in the dorsal plane (along the body length, parallel to the dorsum of the dog), locating the aorta and caudal vena cava in long axis. Ultrasonography of adrenal glands in dogs does not require anaesthesia. The sub-costal approach was found to be the best approach to scan left adrenal gland using a 7.5 MHz linear transducer. This ultrasonographic examination protocol may assist in the diagnosis of pathologies of the adrenals or other organs.

Keywords: Ultrasonography, adrenal glands, healthy dogs

Introduction

Ultrasound has quickly become an important modality for the evaluation of adrenal glands in the small animal patient. The adrenal glands are key components of the endocrine system, and their deranged function can produce a wide range of clinical signs. Adrenal glands cannot be detected with radiography (Kealy *et al.*, 2012)^[8], unless severely enlarged or mineralized. The ultrasonographic assessment of the glands is now considered part of a complete abdominal scan in dogs. The advantages of ultrasonography include the ability to image both normal and abnormal glands, the ease and rapidity of the procedure, the lack of the need for anesthesia, and the availability of ultrasound to practitioners. However, the challenge of imaging the adrenal glands should not be underestimated. Even for an experienced sonographer, the small size of the glands; the deep and sometimes variable position of the glands are the factors of difficulty in evaluation of adrenal glands. Different parameters such as size, shape, margins, echogenicity and structure can be evaluated with ultrasonography. However, ultrasonography is equipment and user-dependent and multiple influencing factors may disturb the examination (Tidwell *et al.*, 1997)^[14].

Material and methods

The present study was conducted in the department of veterinary surgery and radiology at the Teaching Veterinary Clinical Complex (TVCC), (Kothari veterinary hospital), College of Veterinary Science and Animal Husbandry, U. P. Pt Deen Dayal Upadhyaya Pashuchikitsa Vigyan Vishwavidyalaya Evam Go Anusandhan Sansthan, Mathura (UP) INDIA during 2017-2018.

Experimental animals

Eighteen apparently healthy dogs divided into three age groups consisting of 6 animals each; group I: 1-9 months, group II: > 9 months up to 6 yr, group III: > 6 yr.

Ultrasound machine

The adrenal glands of the animals were scanned using the Esaote® MyLab30vetGold, (Esaote Europe B.V., Philipsweg 1, 6227 AJ Maastricht, the Netherlands) with 7.5 MHz linear transducer LA523.

Restraint and Anaesthetic protocol

The animals were subjected to ultrasonographic examination without using any anaesthesia or sedatives with animals restrained in lateral recumbency

Site preparation

An area immediately behind the last rib, cranially below the tips of lumbar transverse process dorsally was shaved neatly, for scanning the left adrenal. Similarly, for right adrenal gland the area extended cranially up to the last intercostal space.

Method of scanning

The adrenal glands were scanned by placing the transducer in the sub-costal area (immediately behind the last rib) in the dorsal plane (along the body length, parallel to the dorsum of the dog), locating the aorta and caudal vena cava in long axis.

Results

The sub-costal approach was found to be the best approach to scan left adrenal gland using a 7.5 MHz linear transducer. The left adrenal gland was scanned by placing the transducer in the subcostal area (immediately behind the last rib) in the dorsal plane (along the body length parallel to the dorsum of the dog) and locating the aorta and caudal vena cava in long axis. The transducer was then slid cranially along to the level of the left kidney keeping the aorta in view and the left renal artery and vein were located. The transducer was rotated 45

degrees clockwise and gently swept cranial to the renal artery and vein to locate the left adrenal gland in long axis. The aorta and kidney were not always visible in the same field of view when the adrenal gland was imaged but in some ultrasonograms many structures, namely, the adrenal gland along with aorta and kidney were visualized in the same field. For locating of the right adrenal gland, the dog was placed in left lateral recumbency. The transducer was placed behind the last rib in the sub-lumbar area, in all the animal and intercostal approach was not needed to locate the right adrenal gland. The aorta and caudal vena cava were again located in the long axis in the dorsal plane. The transducer was then slid cranially, keeping the caudal vena cava in view. The adrenal gland was located along side and dorsal to the caudal vena cava. For measuring the length, the longitudinal sectional views of each adrenal were frozen when maximum length was visible. Similarly, for width measurement the image was frozen when maximum width of either of the poles was visible. The length, width of the cranial pole and the width of the caudal pole were measured on these frozen images of adrenal using the in-built callipers. The left adrenal gland was found easier to scan in comparison to right adrenal gland just because of the position of right adrenal gland. Ultrasonograms were recorded in sagittal plane as it was too difficult to differentiate between adrenal gland and surrounding structures in transverse plane.

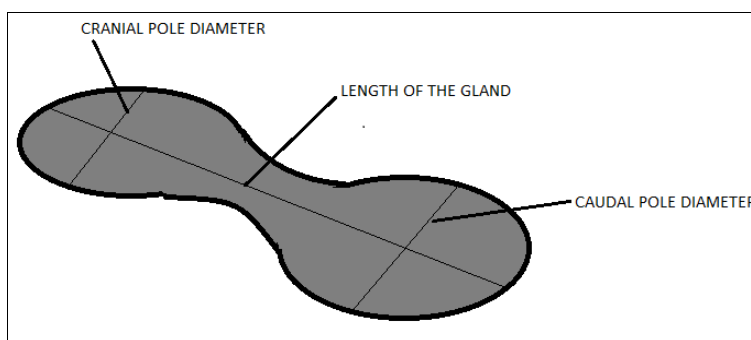


Fig 1: The different measurements of adrenal gland

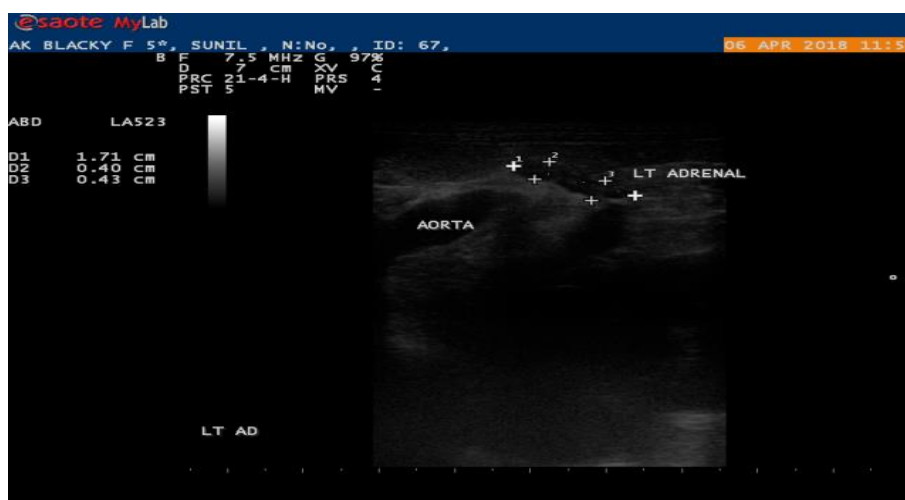

Fig 2: Ultrasonogram showing measurements taken of left adrenal gland with the help of measuring calliper. +1 of the calliper is showing the length taken of the gland. +2 of the calliper is showing the diameter of cranial pole. +3 of the calliper is showing the diameter of caudal pole.

Discussion

In this investigation the left adrenal was scanned in lateral recumbency in all the animal groups as left adrenal gland in right lateral recumbency and right adrenal gland in left lateral

recumbency. Grooters *et al.* (1996) [6] have used dorsal recumbency for scanning adrenals, similarly Mogenicato *et al.* (2011) [9] have advocated dorsal approach whereas, Rose *et al.* (2017) [11] have used both dorsal and lateral recumbent

position for scanning the adrenal glands. However, Soulsby *et al.* (2014)^[13] and Douglass *et al.* (1997)^[5] have used lateral recumbency for scanning the adrenal glands. None of the animals was subjected to sedation or anesthesia. The method of scanning was similar as used by Barthez *et al.* (1998)^[2] and Sandhya *et al.* (2015)^[12]. The rotation angle of transducer was approximately 40°- 45° to obtain a longitudinal view of the adrenal gland. Sandhya *et al.* (2015)^[12] have also used 45° rotation so as to obtain an optimum quality sonogram. Whereas, Barthez *et al.* (1998)^[2] have reported the use of the rotation angle of transducer of approximately 10° to 15°. The approach for both left and right adrenal gland was subcostal positioning the transducer slightly obliquely longitudinally. Some workers have also suggested an intercostal approach for scanning the right adrenal however this approach was not needed to scan the right adrenal gland in the present study. Grooters *et al.* (1996)^[6] have also preferred subcostal rather than intercostal approach especially for measuring adrenal thickness. It was much easier to scan the left adrenal gland in comparison to right adrenal gland just because of the position of right adrenal gland. Grooters *et al.* (1996)^[6] and Barthez *et al.* (1995)^[1] have also reported that it is more difficult to visualize the right adrenal gland in comparison to the left adrenal gland. All the animals were scanned with the linear transducer at a 7.5 MHz frequency, which resulted in images of an optimum resolution. Besso *et al.* (1997)^[3, 14] and Kealy *et al.* (2012)^[8] have also proposed that the frequency of 7.5 MHz with linear transducer allows a better resolution and anatomical details. Grooters *et al.* (1996)^[6] have used 7.5 and 5.0 MHz, Douglass *et al.* (1997)^[5] have used 7.0 and 5.0 MHz, Hoerauf & Reusch (1999)^[7] used only 7.5 MHz sector transducer, Wenger *et al.* (2010)^[15] also used 7.5 MHz, Mogenicato *et al.* (2011)^[9] used 6 – 10 MHz convex probe, Choi *et al.* (2011) used 10.0 MHz linear or 7.5 MHz convex, Pagani *et al.* (2016)^[10] used both, 7.5 – 12 MHz linear and 5.5 – 6.6 MHz micro-convex transducer, Soulsby *et al.* (2014)^[13] used 8 – 5 MHz or 5 – 2 MHz curved array transducer whereas, Rose *et al.* (2017)^[11] used 8 – 5 MHz curvilinear and occasionally a 13 – 5 MHz linear transducer, depending on the size of the dog. All the ultrasonograms were recorded in sagittal plane, because it was too difficult to differentiate the gland in transverse plane. Soulsby *et al.* (2014)^[13] defined sagittal plane as the long axis of adrenal gland length and thickness were both maximal.

Conclusion

Ultrasonography of adrenal glands in dogs does not require anaesthesia. Subcostal approach was found to be the best approach to scan left and right adrenal glands. The scanning of adrenal glands can be easily done using a 7.5 MHz Linear transducer.

References

1. Barthez PY, Nyland TG, Feldman EC. Ultrasonographic evaluation of the adrenal glands in dogs. *Journal of the American Veterinary Medical Association.* 1995; 207:1180-1183.
2. Barthez PY, Nyland TG, Feldman EC. Ultrasonography of the adrenal glands in the dog, cat, and ferret. *Veterinary Clinics of North America: Small Animal Practice.* 1998; 28:869-885.
3. Besso JG, Penninck DG, Gliatto JM. Retrospective ultrasonographic evaluation of adrenal lesions in 26 dogs. *Veterinary Radiology & Ultrasound.* 1997; 38:448-455.
4. Choi J, Kim H, Yoon J. Ultrasonographic Adrenal Gland Measurements in Clinically Normal Small Breed Dogs and Comparison with Pituitary-Dependent Hyperadrenocorticism. *Journal of Veterinary Medical Science.* 2011; 73(8):985-989.
5. Douglass JP, Berry CR, James S. Ultrasonographic adrenal gland measurements in dogs without evidence of adrenal disease. *Veterinary Radiology & Ultrasound.* 1997; 38:124-130.
6. Grooters AM, Biller DS, Theisen SK, Miyabayashi T. Ultrasonographic characteristics of the adrenal glands in dogs with pituitary-dependent hyperadrenocorticism: comparison with normal dogs. *Journal of Veterinary Internal Medicine.* 1996; 10:110-115.
7. Hoerauf A, Reusch C. Ultrasonographic evaluation of the adrenal gland in six dogs with hypoadrenocorticism. *Journal of the American Animal Hospital Association.* 1999; 35:214-218.
8. Kealy KJ, Mcallister H, Graham JP. *Radiografia E Ultrasonografia De Cão E Gato.* Elsevier: Iowa, 2012, 165-172.
9. Mogenicato G, Lamour CL, Conchou F, Diquelou A, Raharison F, Sautet J *et al.* Ultrasonographic evaluation of adrenal glands in healthy dogs: repeatability, reproducibility, observer-dependent variability, and the effect of body weight, age, and sex. *Veterinary Record, BMJ publishing group.* 2011; 168(5):130.
10. Pagani E, Tursi M, Lorenzi C, Tarducci A, Bruno B, Mondino ECB *et al.* Ultrasonographic features of adrenal gland lesions in dogs can aid in diagnosis. *BMC Veterinary Research.* 2016; 12:267.
11. Rose AM, Johnstone J, Finch S, Beck C. Effect of recumbency on ultrasound measurement of normal canine adrenal glands. *Veterinary Medicine: Research and Reports.* 2017; 8:87-96.
12. Sandhya MB, Thirunavukkarasu PS, Kavitha S, Baranidharan GR. Ultrasonography Of Adrenal Glands In Normal And Hyperadrenocorticoid Dogs. *International Journal of Current Research.* 2015; 5:16119-16122.
13. Soulsby SN, Holland M, Hudson JA, Behrend EN. Ultrasonographic evaluation of adrenal gland size compared to body weight in normal dogs. *Veterinary Radiology and Ultrasound,* 2014, 1-10.
14. Tidwell AS, Penninck DG, Besso JG. Imaging of adrenal gland disorders. *Veterinary Clinics of North America: Small Animal Practice.* 1997; 27:237-254.
15. Wenger M, Mueller C, Kook PH, Reusch CE. Ultrasonographic evaluation of adrenal glands in dogs with primary hypoadrenocorticism or mimicking disease. *Veterinary Record.* 2010; 167:207-210.