



E-ISSN: 2320-7078

P-ISSN: 2349-6800

JEZS 2019; 7(2): 1048-1053

© 2019 JEZS

Received: 17-01-2019

Accepted: 21-02-2019

Majid Shafi

Faculty of Veterinary Sciences
and Animal Husbandry, Division
of Veterinary Pathology
Mhow Veterinary College,
Indore, Madhya Pradesh, India

Shabia Shabir

Faculty of Veterinary Sciences
and Animal Husbandry, Division
of Veterinary Pathology
Mhow Veterinary College
Indore, Madhya Pradesh, India

In vivo evaluation of diclofenac induced sub-acute toxicity in Japanese quails

Majid Shafi and Shabia Shabir

Abstract

This experimental work was conducted to elucidate the *in vivo* evaluation of diclofenac induced sub-acute toxicity in Japanese quails. For this study, 100 apparently healthy Japanese quail's birds of either sexes were randomly divided into control and treatment groups comprising of 50 birds in each group. The birds in treatment group were given 10 mg/kg body weight of diclofenac sodium for 10 days. The intoxicated birds revealed moderate lesions of gout characterized by deposition of white chalky urates on the organ surface. The intoxicated birds also revealed nephropathy and immunosuppression as evident by the depletion of lymphoid tissue from the lymphoid organs.

Keywords: Diclofenac, immunosuppression, toxicity, lymphoid organs and gout

Introduction

Non-steroidal anti-inflammatory drugs (NSAIDs) are commonly used to reduce pain in various diseases and postoperative conditions. NSAIDs are anti-inflammatory, antipyretic and analgesic in nature. They produce their effect by inhibiting the activities of cyclo-oxygenases enzymes. Diclofenac sodium was found to cause pathological changes in the kidneys of the vultures, which ultimately lead to the gout [9]. Hepatotoxicity occurs in rats after the oral administration of diclofenac sodium [16]. Broiler birds died due to visceral gout at 24 hours interval after post administration of diclofenac sodium [11]. The toxic effect of diclofenac sodium in ruminants was evident by nephropathy in association with abomasal and ruminal ulcers [15]. In this study, four calves were administered diclofenac @ 3 mg/kg, twice a day for four consecutive days. At the end of experiment, diclofenac treated calves revealed significant increase in transaminase enzymes and significant decrease in haemoglobin concentration. At necropsy, they found abomasal, duodenal and rumen ulcers. Nephritic changes were characterised by cellular swelling of epithelial lining in proximal convoluted tubule, distal convoluted tubule and collecting ducts. Glomeruli revealed hyper cellularity, hyper segmentation and hyperplasia of mesangial cells. An outbreak of gout in poultry revealed emaciated and dehydrated carcasses with moderate enlargement of hock and phalangeal joints. The gross changes were suggestive of concurrent visceral and articular gout. Dry patches of white chalky urate deposits were observed on the breast muscles, neck and on serosal surfaces of pericardium. The urates were observed on kidneys, in the pericardial sac and over the pericardium, liver, spleen, lungs and air sacs. Nephropathy was characterized by enlargement of kidneys. Viscid thick mass of white urates were observed in most of the joints and over the tendon sheath. Deposits were also observed in almost all other joints including shoulder, elbow and toe joints in the limbs [7].

Keeping the above facts in view, this investigation was designed to study the path morphological changes of diclofenac induced subacute toxicity in Japanese quails.

Materials and Methods**Experimental Birds**

A total number of 100 one-day old Japanese quails were procured from the local market of Indore situated in the vicinity of faculty of veterinary sciences. All the birds were already vaccinated against Marek's disease prior to the delivery. On the first day of procurement the birds were given electrol in water in the fore noon. From the afternoon the birds received starter mash.

Correspondence**Majid Shafi**

Faculty of Veterinary Sciences
and Animal Husbandry, Division
of Veterinary Pathology
Mhow Veterinary College,
Indore, Madhya Pradesh, India

Housing

The room was thoroughly cleaned and every part of the room was flamed. Next day white washing of the room was carried out and 24 hours prior to housing of the birds, the room was further fumigated with a potassium permanganate and formalin. The birds were housed in the deep litter system and a floor space of 2 square feet was provided to each chick. The birds in Toxicity and control groups had separated with wire mesh. Thoroughly dried and disinfected chopped paddy straw was used as bedding for the Japanese quails birds.

Feeding

All the birds irrespectively of their groups were maintained on the same type of starter mash. The birds of each group had a separate feeding and watering trays. The birds were fed in the first week @ of 10g/bird but from second week onwards *ad.lib*. Feeding was adopted. Clean tap water mixed with electrolyte @ 10g/100 birds were given to the birds.

Vaccination

All the birds were vaccinated against Marek's disease on the first day of hatching whereas F1 (Lasota) vaccination against Ranikhet disease was carried out to all birds on 6th day of age.

Experimental Groups

The birds were reared up to 2 weeks of age. After that the birds were divided into two groups i.e. treatment group and the control group. Experiment was carried out on 100 birds out of which 50 birds were kept in each group. The control group received normal feed, while other treatment group received diclofenac @ 10 mg/kg body weight for ten days.

Gross pathology

All the surviving experimental birds were killed at the end of experimental period and each organ was critically examined for macroscopic lesions. The lesions were recorded compared at the end of the experiment.

Histopathology

All the dead and killed birds were subjected to detailed necropsy examination. At necropsy table, pieces of different organs like liver, kidneys, heart, lungs, intestine, spleen, bursa, thymus, joints and brain were collected and fixed in 10% buffered formalin for histopathological examination. Later, paraffin embedded tissue sections were cut at 5 µm thickness, thereafter, stained with Haematoxylin and Eosin (H & E) stain and examined under microscope [16].

Experimental Findings

Clinical Signs

The affected birds exhibited retarded growth, twisted necks and lameness. The emaciation and dehydration was noted in the first week of study period. The clinical signs were more evident in birds after 7th days of post intoxication. The intoxicated birds revealed depression, drowsiness, inappetence, huddling together, drooping of wings, laboured breathing, lowering of head, ruffled feathers and weakness. The respiratory movements were decreased and birds appeared to have difficulty in breathing. These intoxicated birds appeared pale head and shrunken comb. The clinical signs observed may include lameness, abnormal bending of the tibial bones, enlarged hock joints, sternal recumbency, convulsion, lacrimation, profuse salivation, diarrhoea, restlessness and ataxia. The keel bone appeared sharp due to

emaciation. At the end of the experimental period, the intoxicated birds which survived for few days revealed retarded growth, watery droppings, muscle weakness and staggering gait. The intoxicated birds stood motionless for long period of time with the feathers puffed and closed eyes. The birds showed repeated sneezing and fluid came out from mouth which appeared to be clogged.

Results

Kidneys

The birds revealed severe gross lesions of gout in Kidneys which was evident by deposition of white chalky materials on capsular surface. Microscopically the tubular epithelium revealed hydropic degeneration with accumulation of eosinophilic hyaline mass in the lumen of tubules. De Galantha stained section with black coloured urate crystals (Fig. 1). The succumbed birds revealed congestion and diffuse hemorrhages with infiltration of mononuclear cells comprising macrophages and lymphocytes in the interstium. The tubular epithelium of the affected birds were hypertrophied and appeared tall columnar sheet like structure protruding into the tubular lumens. Renal tissue showed deposition of tophi appearing as pink coloured radiating amorphous structure in the Bowman's capsule, tubules and interstitial tissue.



Fig 1: Photograph showing De Galantha stained section with black coloured urate crystals

Liver

The birds revealed moderate degree of gross lesions of gout showing deposition of chalky white urates on the capsule of liver. Histopathologically, the birds revealed variable degree of cloudy swelling and periportal fatty changes in the hepatocytes along with multifocal areas of necrosis (Fig 2). Apoptotic bodies may be also observed in the vicinity of necrotic foci which are characterized by basophilic mass inside the hepatic cell.

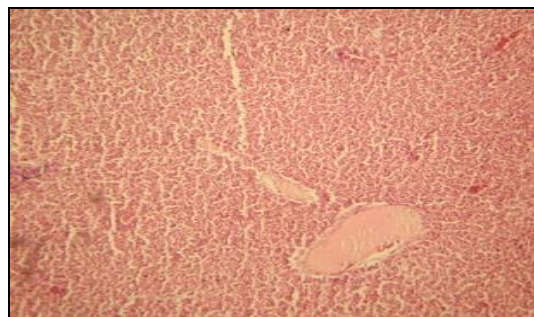


Fig 2: Degeneration and necrosis in liver

Heart

Grossly the affected birds revealed marked gross lesion as

evident by deposition of white chalky material on the pericardium giving frosty appearance to the heart. Microscopically, necrotic changes in the myocardium and proliferation of mesothelial cell are observed in the affected birds. The degenerative changes was observed in the affected birds which is characterized by cytoplasmic eosinophilia, nuclear pyknosis and nuclear rarefaction. The affected birds also revealed degeneration of myocytes characterised by cytoplasmic rarefaction giving vacuolar appearance, associated with mild mononuclear cell infiltration. Disruption of muscle fibers were also be observed (Fig. 3)

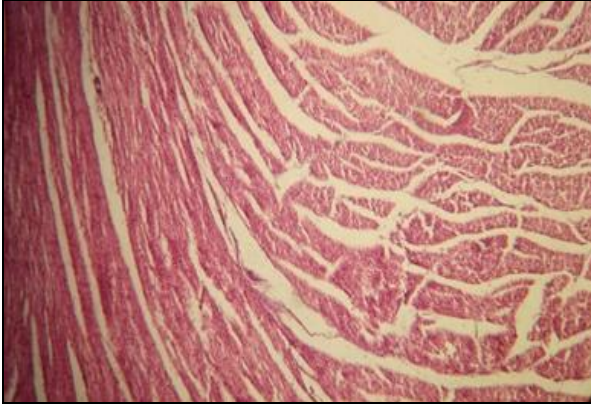


Fig 3: Degeneration and Disruption of Muscle fibers

Lungs

Grossly, the lungs of affected birds revealed vascular congestion, hemorrhages, consolidation and edema formation. The succumbed birds may show the deposition of urates on the lung surface. In most of the cases lungs are emphysematous in nature and air vesicles are filled with edematous fluid. Microscopically, the succumbed birds revealed lesions of congestion and pneumonia which is characterized by the presence of necrotic tissue and infiltration of lymphocytes predominantly in air vesicles, bronchi and bronchioles (Fig 4).

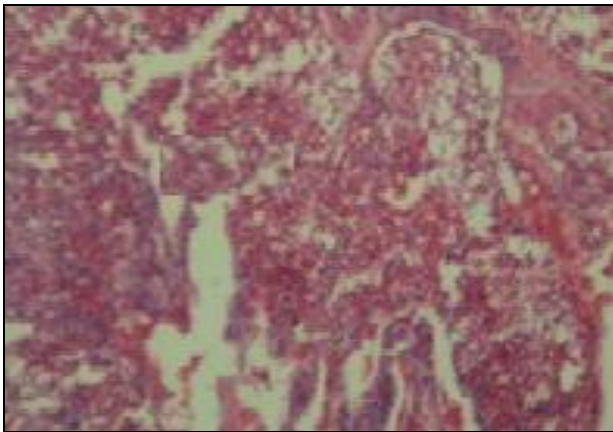


Fig 4: Lung showing congestion and pneumonia

Proventriculus

The succumbed birds revealed urate deposition on the serosal surface of the proventriculus. Microscopically, the succumbed birds showed degeneration and desquamation of epithelial lining of the mucosal folds with presence of cellular debris in the lumen of proventriculus. The succumbed birds also revealed desquamation of epithelium along with hyperplasia of the parietal cells (Fig 5).

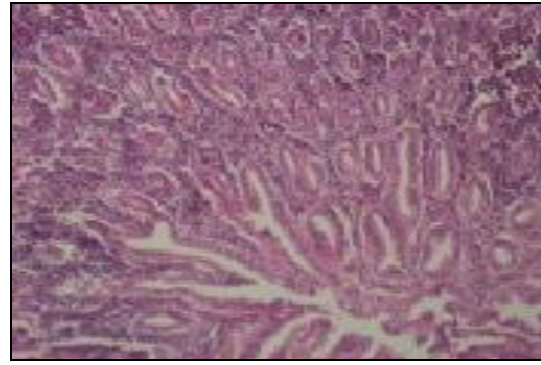


Fig 5: Proventriculus showing degeneration of mucosa.

Crop

Crop revealed generalized edema and marked degeneration of mucosa (Fig. 6). Microscopic examination of crop tissues revealed presence of lymphoid aggregates in the walls. Histopathology in some cases revealed severe desquamation of mucosa together with proliferation of stratified squamous epithelium.

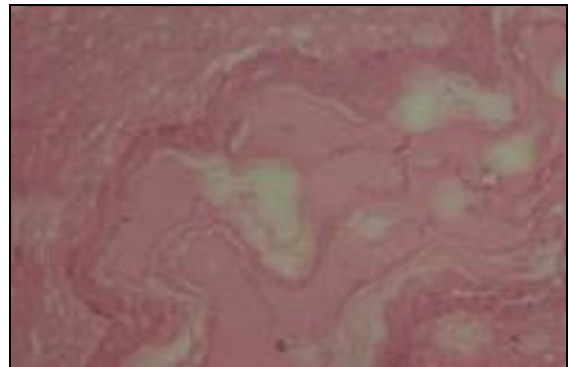


Fig 6: Crop showed edema and degeneration of mucosa

Thyroid

Generally thyroid revealed vascular congestion and hemorrhages. Histopathology of thyroid revealed severe hypertrophied thyroid follicles filled with colloid material (Fig.7).

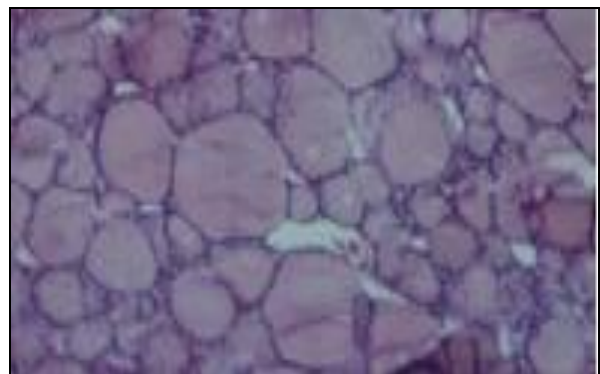


Fig 7: Hypertrophied thyroid follicles

Gizzard

Grossly the succumbed birds revealed white chalky material deposited on the serosal surface of the Gizzard. Microscopically, the glandular epithelium of mucosa of gizzard in succumbed birds showed marked depletion of keratinized layer along with desquamation of glandular epithelium. There may be the complete degeneration of

epithelium observed in affected birds under microscopic examination (Fig. 8).

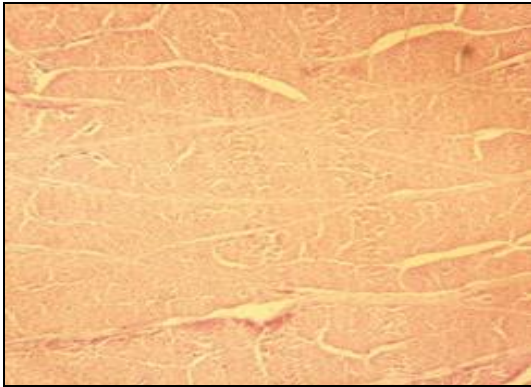


Fig 8: Degenerative changes in Gizzard

Intestine

The intestine of affected birds revealed hamemorrhages and thickened mucosa. Microscopically, necrotic changes were observed in the mucosa of the intestine (Fig.9). The lining epithelium of intestinal mucosa generally revealed degeneration with the presence of mucoid exudate in the lumen. The affected Birds also revealed marked degeneration, necrosis and denudation of mucosa. Villi appeared atrophied with dilatation of crypts. There also be submucosal oedema and mononuclear cell infiltration in lamina propria.

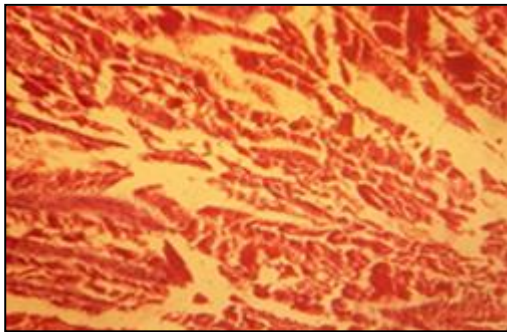


Fig 9: Necrotic changes in the intestinal mucosa

Caecum

The succumbed birds revealed moderate vascular congestion, degeneration and necrosis of Caecum. The affected Birds may also show cellular infiltration in the lamina propria, distortion of villi, necrosis and denudation of mucosa (Fig.10). In severe cases, Caecum may reveal desquamation of epithelial cells and submucosal oedema.

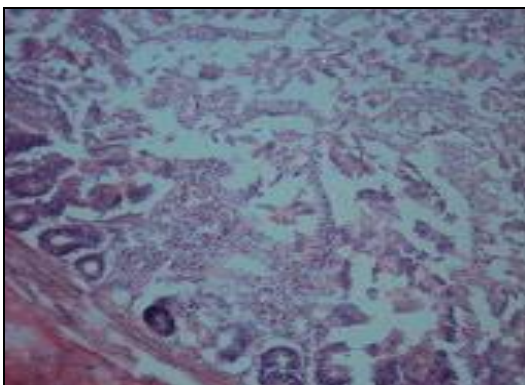


Fig 10: Caecum showing necrosis and denudation of mucosa

Bursa

The succumbed birds showed moderate degree of white chalky material deposited on the surface of the bursa. Microscopically, there was severe depletion of lymphoid tissue from the lymphoid follicles of bursa (Fig 11).

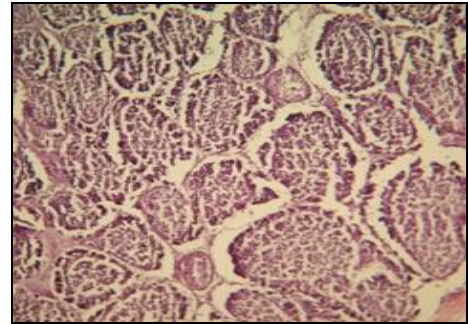


Fig 11: Depletion of lymphoid tissue from lymphoid follicles

Spleen

The affected birds showed deposition of white chalky material on the surface of the spleen. Microscopically, the affected birds revealed proliferation and desquamation of endothelium lining of the central artery. There was depletion of lymphoid tissue in the malphigian corpuscles of spleen (Fig.12). Vascular congestion, hemorrhages, moderate rarefaction of periarteriolar lymphoid sheath and histiocytosis was also evident in the affected birds.

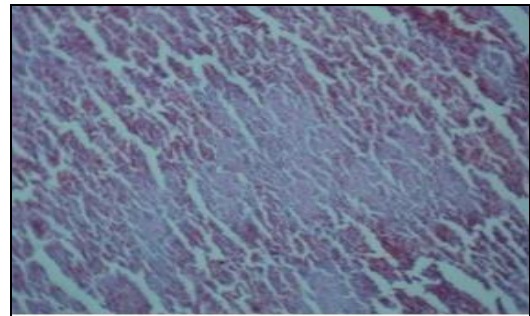


Fig 12: Depletion of lymphoid tissue in spleen

Thymus

The succumbed birds revealed moderate degree of chalky white material deposited on thymus surface. Degenerative changes were observed along with depletion of lymphocytes in the thymus which was as evident by empty spaces in the lymphoid follicles of thymus (Fig.13). In severe cases, there was complete degeneration of thymic lobules and interstitial fibrous tissue proliferation

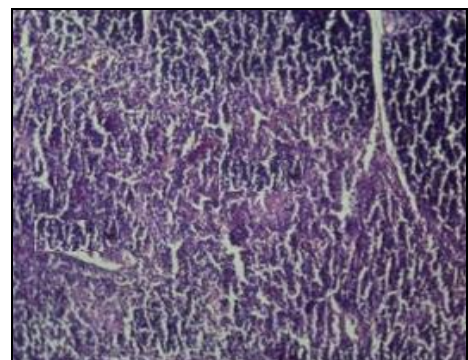


Fig 13: Degeneration of thymic lobules along with lymphoid depletion

Joints

The intoxicated bird showed swollen hock and toe joints. Microscopically, the succumbed birds revealed white chalky material deposited on the articular surfaces along with tendon sheath of the joints.

Brain

The succumbed birds revealed congestion in the brain. Microscopically there may be perineuronal edema in cerebral cortex of the brain. There were varying degrees of neuronal degeneration and necrosis associated with gliosis especially in the perivascular areas (Fig. 14). The necrotic pyramidal cells appeared shrunken and stained darker with haematoxylin



Fig 14: Neuronal Degeneration

Discussion

The Kidney of intoxicated birds revealed moderate lesions of gout and interstitial nephritis. Microscopically, hydropic degeneration along with accumulation of eosinophilic hyaline mass in tubular lumen was observed in the affected birds. The results were comparably similar with the findings of diclofenac toxicity in mice^[5].

The liver of sacrificed birds revealed dilation of sinusoid, fatty changes in hepatocytes and necrosis. Microscopic examination also revealed presence of several apoptotic bodies near the necrotic foci. Similar results were documented in diagnostic investigation of vulture mortality^[9]. Grossly, the heart showed enlargement, petechiae haemorrhages and deposition of white chalky material with increased amount of pericardial fluid. Microscopically, the lesions of heart revealed zenkers degeneration, separation of my fibers and vascular congestion in the endocardium of intoxicated birds. The results were justified by the findings of earlier researchers who worked on Path morphological effect of gout in poultry^[17]. There was deposition of urate crystals on the lung of intoxicated birds. Microscopically, the succumbed birds revealed oedema, necrosis and pneumonia characterized by infiltration of heterophils and mononuclear cells in the affected lung tissue. These results were in accordance with the results of gout in poultry^[12].

The Proventriculus of intoxicated birds revealed urate deposition, degeneration, desquamation and hyperplasia of the parietal cells. Similar results were earlier documented in diclofenac toxicity in broilers^[4]. Diclofenac causes pathological changes in the crop, lungs and air sacs of the intoxicated birds leading to the gout. Microscopically, the crop revealed edema and marked degenerative changes in mucosa. These results are similar to the findings of diclofenac toxicity in vultures^[14]. The gizzard of intoxicated revealed

hyperplasia of the parietal cells. Microscopically, there was depletion of keratinized layer and desquamation of glandular epithelium. The results were comparably similar with the findings of gout in Kashmir Favorella Poultry^[7]. The Intestine of birds revealed deposition of white chalky material on intestines. Microscopically, necrotic changes were observed in the mucosa of the intestine. Similar findings were reported earlier by the researchers in the diclofenac toxicity in vultures^[1]. The intoxicated birds showed deposition of white chalky material on the bursa. Histopathologically, there was severe depletion of lymphoid tissue from the lymphoid follicles of bursa. These findings were in accordance with the results of gout in poultry published earlier in print media^[7].

The spleen and thymus of intoxicated birds revealed urate deposition and depletion of lymphoid tissue. The results were justified by the findings observed in pyrethroid toxicity in broiler chickens^[3]. The Hock and toe joints of intoxicated bird's revealed swollen and painful condition of joints. The intoxicated birds reveal moderate degree of white chalky materials deposited on the articular surfaces along with the tendon sheath of the joints. Similar results were documented in an outbreak of gout in Poultry^[8]. The post mortem examination of intoxicated birds revealed congestion and edema in the brain. Microscopically, the succumbed birds showed leptomenigeal congestion along with perivascular and perineuronal edema in cerebral cortex of the brain. The results were comparably similar with the findings of sodium bicarbonate toxicity in Korean Native Broilers^[2].

Conclusion

It was concluded that diclofenac is toxic to birds, resulting in severe clinical toxicosis and even death with acute intoxication or slow intoxication with repeated exposures. This is especially important in view of rapid decline of bird populations recorded over past few decades.

References

1. Arun R, Azeaz P. Decline of Vulture population by diclofenac toxicity. *Current. Science Journal*. 2004; 87(5):565-568.
2. Ejaz S, Lion CW. Gout induced by intoxication of Sodium Bicarbonate in Korean Native Broilers. *Journal of Chemical Toxicology*. 2005; 28:245-261.
3. Garg UK, Asim KP. Immuno-pathophysiological effects of chronic toxicity with pyrethroid in broiler chicks. *International Immunopharmacology*. 2004; 4:1709-1722.
4. Gajera AB. Pathological studies on experimental feeding of diclofenac sodium in broilers, Anand Agriculture Universality, MV. Sc thesis, 2006.
5. Hickey E, Ray D. Diclofenac induced in-vivo nephrotoxicity in mice. *Free Radical Biology and Medicine*. 2001; 31(2):139-152.
6. Lillie RD. *Histological Technique and Practical Histochemistry*. The Blakistan Div. McGraw Hills Book Company, Toranto, 1954.
7. Mir MS, Darzi MM. Investigation of an outbreak of gout in Kashmir Favorella Poultry. *Indian Journal of Indian Veterinary Pathology*. 2005; 29(1):35-37.
8. Nayak NC, Chakarbarti A. An outbreak of Gout in Poultry in west Bengal. *Journal of the Indonesian Veterinary Research*. 1999; 65(12):1080-1081.
9. Oaks JL, Khan A. Diagnostic investigation of vulture mortality *Indian Veterinary Journal*. 2004; 23:152-158.
10. Pandey S. Toxic pathological studies of acetyl salicylic

- acid, nimesulide and diclofenac sodium in broiler chicks. Anand Agricultural University, M.V.Sc thesis. Anand, 2014.
11. Patel AK. Epidemiological and Experimental studies on etiology of visceral gout in broiler chicks, Anand Agricultural University, M.V.Sc thesis. Anand, 2005.
 12. Reddy M, Sudhakar R. Occurrence of Gout in the poultry specie. Poultry Guide. 1984; 21:77.
 13. Rao B, Sharma R. An outbreak of gout in poultry in East Godavari District, Andhra Pradesh. Poultry Adviser. 1993; 26(4):43-45.
 14. Shultz S, Prakash V. Diclofenac poisoning is wild spread in declining vulture population across Indian Sub-continent. Proceedings of the Royal Society of London, 2004, 1098-1099.
 15. Shridar N, Narayanan K. Study of Diclofenac toxicity in calves. Indian Veterinary Journal. 2007; 84:141-143.
 16. Tang W. The metabolism of Diclofenac Enzymology and Toxicology perspectives. Current Drug Metabolism. 2003; 21:135-138.
 17. Uma CA, Rao R. Path morphological effect of gout in poultry. Indian Journal of Veterinary Pathology. 1999; 23:94-95.