



**E-ISSN: 2320-7078**  
**P-ISSN: 2349-6800**  
 JEZS 2019; 7(2): 946-948  
 © 2019 JEZS  
 Received: 16-01-2019  
 Accepted: 21-02-2019

**Dibyajyoti Talukdar**  
 Assistant Professor, Department of  
 Animal Reproduction, Gynaecology  
 & Obstetrics, College of Veterinary  
 Sciences & A.H., Central Agricultural  
 University, Selesih, Mizoram, India

**D Murasing**  
 MVSc. Scholar, Department of  
 Animal Reproduction, Gynaecology  
 & Obstetrics, College of Veterinary  
 Sciences & A.H., Central Agricultural  
 University, Selesih, Mizoram, India

**S M Nadaf**  
 MVSc. Scholar, Department of  
 Animal Reproduction, Gynaecology  
 & Obstetrics, College of Veterinary  
 Sciences & A.H., Central Agricultural  
 University, Selesih, Mizoram, India

**A Kayina**  
 MVSc. Scholar, Department of  
 Animal Reproduction, Gynaecology  
 & Obstetrics, College of Veterinary  
 Sciences & A.H., Central Agricultural  
 University, Selesih, Mizoram, India,

**K Sarma**  
 Associate Professor, Department of  
 Veterinary Medicine, College of  
 Veterinary Sciences & A.H., Central  
 Agricultural University, Selesih,  
 Mizoram, India

**G Kalita**  
 Associate Professor & Head,  
 Department of Livestock Production  
 & Management, College of Veterinary  
 Sciences & AH, Central Agricultural  
 University, Selesih, Mizoram, India

**FA Ahmed**  
 Professor & Head, Department of  
 Animal Reproduction, Gynaecology  
 & Obstetrics, College of Veterinary  
 Sciences & A.H., Central Agricultural  
 University, Selesih, Mizoram, India

**Correspondence**  
**Dibyajyoti Talukdar**  
 Assistant Professor, Department of  
 Animal Reproduction, Gynaecology  
 & Obstetrics, College of Veterinary  
 Sciences & A.H., Central Agricultural  
 University, Selesih, Mizoram, India

## Vulvovaginitis in Holstein: Friesian cow and its therapeutic management

**Dibyajyoti Talukdar, D Murasing, S M Nadaf, A Kayina, K Sarma, G Kalita and FA Ahmed**

### Abstract

The vulva provides an effective protective barrier to uterus from ascending infection in a normal cow. Infectious Bovine Rhinotracheitis (IBR), *E. coli*, *Staphylococcus*, *Streptococcus*, *Proteus*, or *Klebsiella* are the causes of Vulvovaginitis. Present study is a case of vulvovaginitis presented to Teaching Veterinary Clinical Complex with the history of massive vulvar swelling. The animal was treated with antibiotic based on culture and sensitivity and therapeutic management was done with application of ice-pack, anti-inflammatory, Serratiopeptidase bolus and Pop-in spray as intra-vaginal emollient and animal was recover with uneventful.

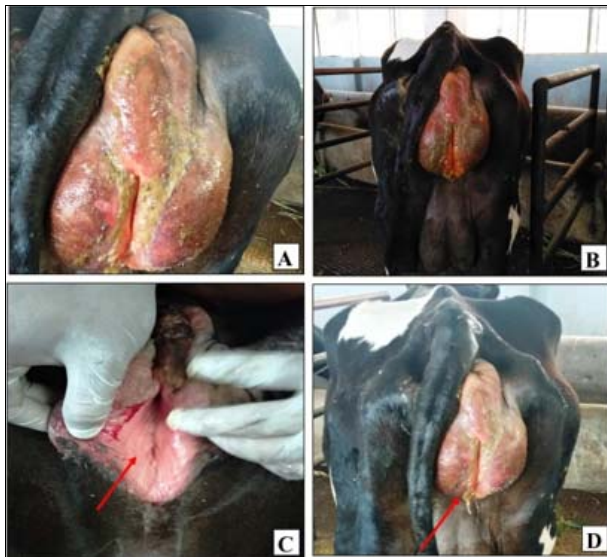
**Keywords:** cow, vulvovaginitis, therapeutic management

### Introduction

In a normal cow, the vulva provides an effective protective barrier to vagina and uterus from ascending infection <sup>[1]</sup>. Multiple viral and bacterial causes of vulvovaginitis have been identified in cattle although vulvovaginitis is intermittently seen in cow <sup>[1]</sup>. It may be concomitant with other causes such as hyperestrogenism caused by persistent oestrus, ovarian remnant disease, or adrenal disease <sup>[2]</sup>. Vulvar swelling also develops during cystitis, crystal Luria, or even aggressive hob mating behaviour but the incidence is less <sup>[1]</sup>. The inadequate sanitation and meagre husbandry may also endorse vaginitis in breeding animals when the animals are kept on particulate bedding like hay, straw, or shavings which may adhere to the swollen vulva during oestrus <sup>[3]</sup>. It is also seen during parturition with trauma and it may develop acute, necrotic, and chronic vaginitis that is either a primary or secondary to chronic endometritis and cervicitis <sup>[2]</sup>. Though cloudy or mucopurulent discharge is the hallmark of vaginitis but does not specifically differentiate the condition from cervicitis or endometritis <sup>[4]</sup>. In certain cases vaginitis is also associated with overgrowth of bacteria such as *E. coli*, *Staphylococcus*, *Streptococcus*, *Proteus*, or *Klebsiella* <sup>[5]</sup>. It can also be differentiated from normal vulvar swelling during oestrus, before parturition by physical examination, and the presence of mucopurulent vaginal discharge in Pyometra <sup>[3]</sup>. Sometime concurrent metritis and fever are occasionally present <sup>[5]</sup>.

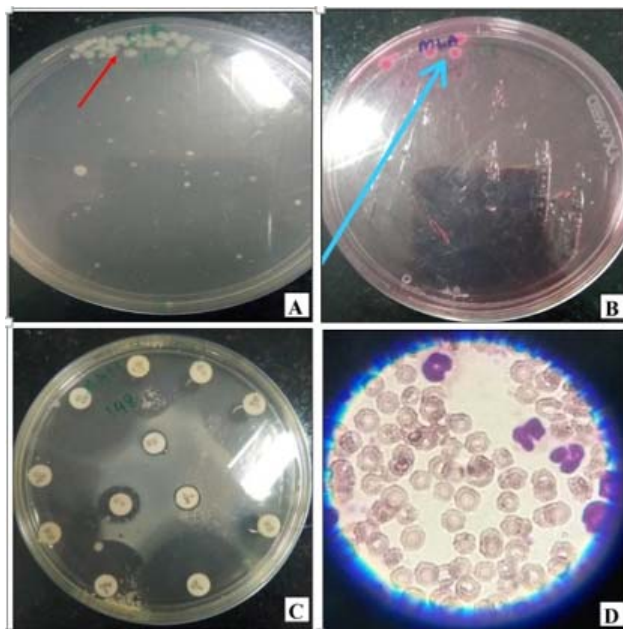
### Case History and Clinical Observation:

A Six years old Holstein- Friesian cow of Instructional Livestock Farm, College of Veterinary Sciences & A.H., Central Agricultural University, Selesih, Aizawl, Mizoram was presented in the Teaching Veterinary Clinical Complex, College of Veterinary Sciences & A.H., Central Agricultural University, Selesih, Aizawl, Mizoram with a history of massive vulvar swelling since early morning. The cow was off fed. On clinical examination, vulva was found inflamed with reddish colouration and little discharge was oozing out from the vulva (Fig. 1 A, B & D). The vulvar mucous membrane was congested and no blister/ pustule were seen (Fig. 1C). The temperature was normal (102°F) and pulse (80/minute) and respiration (34/minute) was slightly increased. By the signs of the case, it was diagnosed as vulvovaginitis. To find out the aetiology, blood and vaginal swab was collected aseptically and vaginal swab sent to Department of Veterinary Microbiology for further processing <sup>[6]</sup>. The EDTA blood was also further analysed for haematological changes.



A. Swelling of the vulva  
 B. Redding of the vulva  
 C. Congested mucous membrane  
 D. Vulvar discharge

**Fig1:** Clinical observation of vulvovaginitis in a Holstein Frisian



A. Culture plate with *Escherichia coli* growth at Nutrient Agar  
 B. Culture plate with *Escherichia coli* growth at MacConkey Lactose Agar  
 C. ABST  
 D. DLC

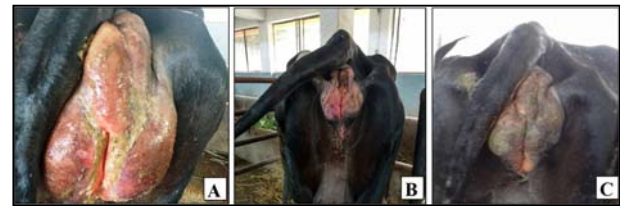**Fig 2:** Bacterial Culture, ABST and DLC

*coli* which was confirmed from the colony growing at Nutrient agar and MacConkey agar (Fig. 2 A & B). ABST result showed sensitivity against e Enrofloxacin, amoxicillin, cephotaxime, ceftriaxone, Streptomycin, Amikacin and tetracycline (Fig. 2 C). DLC count revealed neutrophilia. (Fig. 2 D).

**Treatment:**

The area of vulva was cleaned with KMNO<sub>4</sub> (1:10,000) and immediately after cleaning, ice pack was applied on the

swollen vulva. Then the cow was treated with Enrofloxacin @ 4.5gm / kg body weight daily for 5 days, anti-inflammatory drug Meloxicam @ 0.5mg/kg body weight daily for 5 days and Chlorpheniramine Maleate @ 10ml injected through intramuscular route with Serratopeptidase bolus@ two bolus orally daily for 5 days and Reproductive Care Aerosol Spray Can (Pop-in spray) (Natural remedies) was applied externally over the vulva. Swelling of vulva was reduced after third day of post therapy (Fig. 3 A, B & C). The haematological parameters revealed improvement of neutrophil count after third day of post therapy (Table 1).



A. Before treatment  
 B. 2<sup>nd</sup> Day of post therapy  
 C. 3<sup>rd</sup> Day of post therapy

**Fig 3:** Therapeutic response against vulvovaginitis

**Table 1:** Hematological parameters

Parameters	Before Treatment	After treatment	Normal Range <sup>(7)</sup>
Haemoglobin (gm/dl)	9	10	8-12
ESR (mm in 1 <sup>st</sup> hour)	2	2	2-5
TEC (mm/ 10 <sup>6</sup> )	9	9.5	8-18
WBC(mm/10 <sup>3</sup> )	15	10	8-12
PCV (%)	30	42	50-70
Lymphocytes (%)	60	50	50-75
Neutrophils (%)	70	44	30-48
Eosinophils (%)	8	4	1-8
Monocytes (%)	4	1	0-4
Basophils (%)	1	1	0-1

**Discussion**

The vulva provides an effective protective barrier to vagina and uterus from ascending infection in normal cows <sup>[1]</sup>. IBR, *Escherichia coli* are the likely the causes of vulvovaginitis <sup>[8]</sup>. There may be development of oedema in vulvar region which might be due to excessive leakage of fluid from blood vessels or from impaired lymph drainage <sup>[9]</sup>. Each of the vulvar lip would be perfused and drained from the ipsilateral vessels and lymphatics. The swelling of vulvar lips were bilaterally symmetrical which lowers the likelihood of a unilateral pathology affecting perfusion or drainage <sup>[10]</sup>. Though vulvar oedema is a clinical sign of impending parturition, the physiological vulvar oedema is mild and only occurs shortly before calving <sup>[10]</sup> unlike the massive oedema observed due to *Escherichia coli* as described in this report. The clinical symptoms and gross features of the vulvovaginitis recorded in the present study were in close conformity with the findings of earlier workers <sup>[3]</sup>. Inflammatory Neutrophilia is observed in viral, bacterial, protozoal, parasitic and fungal infection <sup>[11]</sup>. In bovines, neutrophilia is also commonly observed with acute purulent process, such as endometritis, metritis, retained placenta, vaginitis etc. <sup>[11]</sup> which is in agreement with present

case.

Enrofloxacin has demonstrated a significant post-antibiotic effect for both Gram-negative and Gram-positive bacteria and is active in both stationary and growth phases of bacterial replication [12, 13]. In the present study the enrofloxacin giving tremendous result. Whereas, meloxicam was used to treat inflammatory conditions and Chlorpheniramine Maleate was used to stop the histamine secretion [14]. The serratopeptidase bolus showed good result by reducing vulvar swelling within 72 hrs [15] and application of Reproductive Care Aerosol Spray can to gourd the bacterial infection.

### Conclusion

Multiple viral and bacterial agents were responsible for vulvovaginitis although vulvovaginitis is intermittently seen in cow. In the present case study, it was found that *Escherichia coli* was responsible for massive oedema of the vulva with vulvovaginitis. Application of ice-pack, anti-inflammatory, serratopeptidase bolus and Pop-in spray as intra-vaginal emollient were effective treatment of vulvovaginitis in cow.

### References

1. Durrell WB. Infectious Vaginitis in Cattle. Canadian J. Comparative Medicine. 1949; (2)13:32-40.
2. Lawford AM, Scott K, Lust K. A case of massive vulvar oedema due to septic pubic symphysitis complicating pregnancy. Australian and New Zealand Journal of Obstetrics and Gynaecology. 2010; 50:576-577.
3. Crawley J F, Wiills CG, MacGregor KL. Bovine Vaginitis. Canadian Journal of Comparative Medicine. 1950; (1)14:5-10.
4. Yeruham I. Necrotic vulvovaginitis in dairy cattle in Israel Journal of Veterinary Record. 2007; 160:164-166.
5. Radostits OM, Gay CC, Blood DC, Hinchcliff KW. In: Veterinary Medicine.. London: W.B. Saunders Company Ltd. 2000; (9):2-3.
6. Clermont O, Bonacorsi S, Bingen E. Rapid and simple determination of the *Escherichia coli* phylogenetic group. Applied and Environmental Microbiology. 2000; 66:4555-4558.
7. Talukdar DJ, Talukdar P. In: Recent concept on repeat breeding in dairy cattle. Satish Serial Publishing house, New Delhi, India, 2017,
8. Kollannur JD, Syam R, Chauhan RS. Epidemiological Studies on Infectious Bovine Rhinotracheitis (IBR) in Different Parts of India. International Journal of Livestock Research. 2014; 4(5):21-27.
9. Odani JS, Blanchard PC, Adaska JM, Moeller RB, Uzal FA. Malignant edema in postpartum dairy cattle. Journal of Veterinary Diagnostic Investigation. 2009; 21:920-924.
10. Deren O, Bildirici I. Massive vulvar edema complicating a diabetic pregnancy. European Journal of Obstetrics & Gynecology and Reproductive Biology. 2000; 93: 209-211.
11. Tornquist SJ, Weiss DJ, Wardrop KJ, Wiley, Ames, Rigas J, et al. Interpretation of ruminant leukocyte responses. In: Schalm's Veterinary haematology, ed. 2010; 307-313.
12. Plumb DC. Enrofloxacin. In: Veterinary Drug Handbook, fifth edition. Blackwell Publishing, 2121 South State Avenue, Ames, Iowa, 1987,
13. Wetzstein HG, DeJong A. In vitro bactericidal activity

and post antibiotic effect of fluoroquinolones used in veterinary medicine. Compendium on Continuing Education for Practising Veterinarian. 1996; 18(2):22-29.

14. Savaliya KB, Parikh SS. A Unique case of Honey Bee Sting in Gir cow and its Therapeutic management. Scholars Journal of Agriculture and Veterinary Sciences. 2015; 2(4A):285-286.
15. Deka P, Das G. A case report on uterine prolapse in an indigenous cow and its management. International Journal of Science and Research, 2018; 7(6):377-78.