



E-ISSN: 2320-7078

P-ISSN: 2349-6800

JEZS 2018; 6(6): 988-991

© 2018 JEZS

Received: 11-09-2018

Accepted: 12-10-2018

Sharun Khan

MVSc. Scholar, Division of Veterinary Surgery, ICAR-Indian Veterinary Research Institute (IVRI), Izatnagar, Bareilly, Uttar Pradesh, India

Anjana Satheesh

MVSc. Scholar, Department of Veterinary Surgery and Radiology, College of Veterinary and Animal Sciences, Pookode, Wayanad, Kerala Veterinary and Animal Sciences University, Kerala, India

Sabarinadh VR

Emergency Veterinary Surgeon, Nemom Block Veterinary Hospital, Thiruvananthapuram, Animal Husbandry Department, Government of Kerala, Kerala, India

Ranjith Mohan M

Veterinary Surgeon, Veterinary Dispensary, Karimpuzha, Animal Husbandry Department, Government of Kerala, Kerala, India

Syed Aboobacker Sidhique

Veterinary Surgeon, Veterinary Polyclinic, Mannarkkad, Animal Husbandry Department, Government of Kerala, Kerala, India

Shaji Panikkassery

Senior Veterinary Surgeon, Veterinary Polyclinic, Mannarkkad, Animal Husbandry Department, Government of Kerala, Kerala, India

Correspondence**Sharun Khan**

MVSc. Scholar, Division of Veterinary Surgery, ICAR-Indian Veterinary Research Institute (IVRI), Izatnagar, Bareilly, Uttar Pradesh, India

Surgical management of dystocia due to uterine adhesion in a goat

Sharun Khan, Anjana Satheesh, Sabarinadh VR, Ranjith Mohan M, Syed Aboobacker Sidhique and Shaji Panikkassery

DOI: <https://doi.org/10.22271/j.ento.2018.v6.i6.9.01>

Abstract

Dystocia is defined as difficulty in parturition. It is a common condition in small ruminants especially goats. A four year old Malabari goat was presented to Veterinary Polyclinic, Mannarkkad with the history of full term pregnancy and distention of the ventral abdomen. The animal was showing straining intermittently for the past one day without progressing into parturition. Preliminary examinations followed by pervaginal examination identified the need of cesarean section. The goat was sedated using xylazine. Local infiltration analgesia was achieved with 2 % lignocaine hydrochloride at the proposed site of the incision. Left lower abdominal coeliotomy was done. The gravid uterus was identified which was seen attached to the lower abdomen. The uterus was carefully detached from the lower abdominal wall and was lifted towards the incision site. The incision was made on the uterine body. Removed the dead fetus from the uterus. The uterus was sutured, followed by suturing of the peritoneum, muscle layers, and skin. Postoperatively animal was treated with antibiotics for five days. Animals recovered from anesthesia without any complication and made uneventful recovery after the course of antibiotics along with other supportive therapy.

Keywords: Uterine adhesion, cesarean section, goat, dystocia

Introduction

Dystocia is defined as abnormal or difficulty in giving birth [1]. It is a common condition in small ruminants resulting in huge economic losses to farmers either due to death of new-born or dam, it also adversely affects the fertility of dam [2]. The incidence of dystocia is more in goats compared to ewes [3]. Abdul Rahman *et al.* (2000) reported that the incidence of dystocia is about 7% in goats [4]. The cause of dystocia can be divided into the fetal and maternal cause. The fetal causes which include an oversized fetus, fetal malpresentation, fetal malposition, postural defects, and congenital abnormalities [5]. Maternal causes of dystocia is mainly due to a deficient dilatation of the cervical canal (ring womb), narrow pelvis and uterine inertia [6]. Maternal dysfunctions such as uterine rupture and ectopic pregnancy are also reported in causing dystocia in does [7]. Cesarean section is a safe and successful procedure for management of dystocia if performed as early as possible. However, manual traction after correction and hormonal treatment can be attempted, but have reduced success rate [8]. This paper describes a case of dystocia due to uterine adhesion and its surgical management by emergency cesarean section in a goat.

History and Diagnosis

A four year old Malabari goat was presented to Veterinary Polyclinic, Mannarkkad with the history of full term pregnancy and distention of abdomen ventrally for the past few days (Fig. 1). The animal was showing straining intermittently for the past one day. No vaginal discharge was observed and the animal was anorexic. The animal was active and alert and was showing intermittent straining. On detailed clinical examination temperature, respiration, conjunctival mucous membrane, and lymph nodes were normal but were having tachycardia. On pervaginal examination, no fetus could be palpated in the anterior vagina and the cervix was closed. On abdominal palpation, at the ventral swelling, the fetal skeleton could be palpated towards the ventral side. Ultrasonography confirmed that the fetus was dead and the fetus was found in the ventral abdomen near to the abdominal wall. Due to the close proximity of the fetus to the

skin in the lower abdominal region uterine adhesion with the ventral aspect of the abdomen was suspected. The condition was tentatively diagnosed as a case of

dystocia due to uterine adhesion. It was decided to perform an emergency cesarean section to correct the condition.

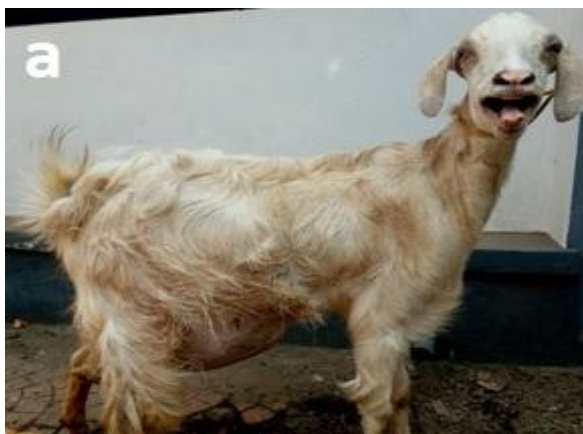

Fig 1a: Full term pregnant goat



Fig 1b: Ventral distention of abdomen

Table 1: Clinical parameters of the goat ^aThe Merk Veterinary Manual- 11th edition (2016).

Parameters	Patient value	Normal range ^a	Remarks
Temperature (°F)	102.7	101.3-103.5	Normal
Respiratory rate (per minute)	26	16-34	Normal
Heart rate (per minute)	92	70-80	Tachycardia
Rumen motility (per two minutes)	2	2-3	Normal
Mucous Membrane	Pale pink	Pale pink	Normal

Anesthesia

The doe was sedated with an intramuscular injection of xylazine hydrochloride at the dose rate of 0.2 mg/ kg body weight. The plane of sedation was achieved within 10

minutes. Done local infiltration anesthesia (inverted L-block) on the left flank using Lignocaine hydrochloride 2% (Fig. 2A).

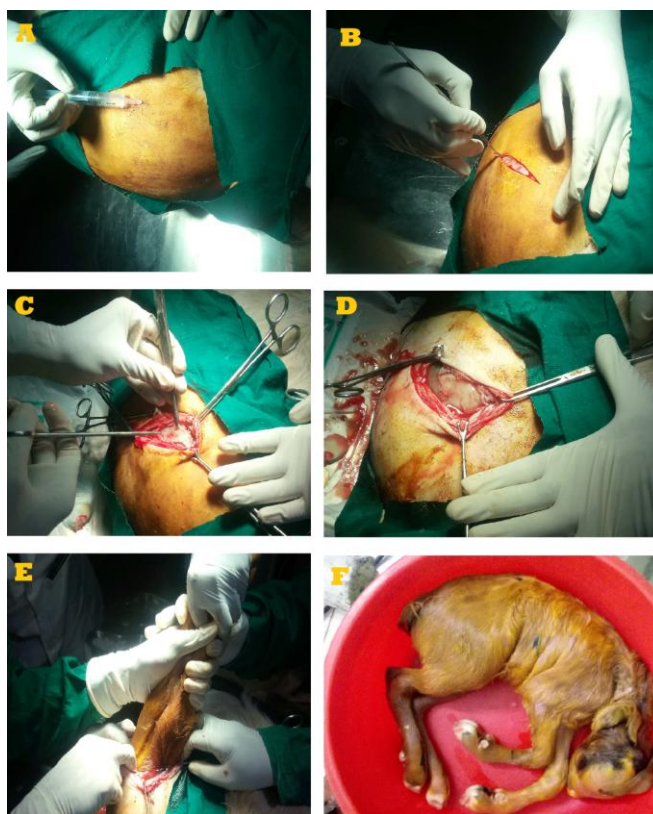


Fig 2A: Local infiltration of lignocaine hydrochloride 2% - Inverted L block. **B:** Oblique bold skin incision is put on the lower left abdominal wall. **C:** Carefully dissected through subcutis and layers of muscle, finally entered the abdominal cavity after incising the parietal peritoneum. **D:** Explored the abdominal cavity and identified the gravid uterus. **E:** Incision on the uterine body and removed the dead fetus by traction. **F:** Dead fetus.

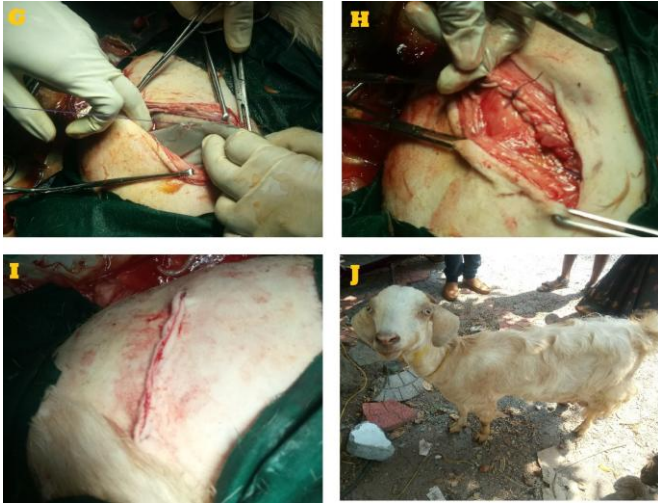

Fig 2G: Uterus was closed in Cushing followed by Lembert suture pattern using vicryl size 2-0. **H:** Muscle layers was closed in simple continuous pattern using vicryl size 1-0. **I:** Apposed the skin incision in horizontal mattress pattern with monofilament nylon. **J:** Animal on the fifth postoperative day.

Surgical Technique

The animal was placed in the surgical table at lateral recumbency. The lateral abdomen was prepared for aseptic surgery by scrubbing with povidone iodine. An oblique skin incision of about 8 cm was made on left flank midway between the last rib and iliac crest extending from 5 inches below the lumbar vertebrae to 1 inch above the mammary vein (Fig. 2B). Minor haemorrhages were controlled through ligation. The fascia was separated by digital manipulation. Muscle bundle was bluntly separated and peritoneum was exposed (Fig. 2C). The parietal peritoneal layer was held raised and a stab incision made in it was extended along the incision line with scissors. The gravid uterus was identified (Fig. 2D) which was attached to the lower abdomen. The uterus was carefully detached from the lower abdominal wall without tearing the uterus and was lifted towards the incision site. The incision was made on the uterine body. Removed the dead fetus from the uterus (Fig. 2E). The uterus and abdominal cavity were washed with sterile normal saline and metronidazole solution.

The uterus was closed using a double layer of inversion sutures – Cushing followed by Lambert using 2-0 vicryl (Fig. 2G). After ensuring that there is no seepage of luminal content into the peritoneal cavity, the uterus was reverted to its original position. Peritoneum along with muscle layers was sutured using size 1-0 vicryl in a simple continuous pattern (Fig. 2H). The subcutaneous tissue was also sutured with size 1-0 vicryl in a continuous pattern. The skin was apposed using nylon by a horizontal mattress suture pattern (Fig. 2I). Post-operatively animal was given Dicrysticin-S^b 2 ml intramuscularly for five days and meloxicam 2 ml intramuscularly for three days. A single dose of tetanus toxoid was also given. Animals recovered from anesthesia without any complication and made uneventful recovery after the five-day course of antibiotics along with other supportive therapy (Fig. 2J).

^bA product of Sarabhai Zydus Animal Health Limited.

Discussion

Dystocia is a major cause in goats leading to loss of kids or dam or both, hence causing economic loss to the farmers. Trauma caused due to the management of dystocia

predisposes to infection thus affecting fertility [9]. The ability to distinguish kidding difficulties at the first sign is important in treating dystocia. Medical management is only an option if dam and fetuses are stable and healthy due to the proper fetal position, presentation and posture without any obstruction. Ring womb, or incomplete cervical dilatation, is a problem in some sheep and goats flocks. It accounted for an incidence of 20 to 30% of all dystocia cases [10]. If there is a delay in treatment of dystocia there is an increased risk of losing the lamb and its mother, and prolonged dystocia in ewes may cause necrotic metritis which is usually fatal [11]. Prolonged dystocia also results in uterine infection and gangrenous metritis, since the retained fetus and the lochia provides a good medium for bacterial multiplication [12].

In the present case the uterus adhered to the lower abdominal wall, sufficient degree of myometrial contractions that is required to initiate the physiological mechanism of parturition like dilatation of cervix and propulsion of fetus could not occur. This was the main reason for dystocia even though the animal had completed the term. Adhesions can be the result of different factors. They are usually formed after trauma, inflammation, ischemia, and infection of the peritoneum, leading to abnormal connections among serosal surfaces due to an imbalance between fibrin deposition and fibrinolysis [13]. In the present case, the goat was reared in an extensive system of rearing so the chance of accidental trauma cannot be ruled out. A similar case of uterine adhesion causing delayed delivery of a co-twin fetus in a sheep was reported by Erdogan *et al.* (2015) which was considered as the first ever case of dystocia due to uterine adhesion in sheep. He also hypothesized that utero-peritoneal adhesion in his case was responsible for the retained fetus because of reduced or absent myometrial contractions [14].

Conclusion

This case points towards the confirmation of the hypothesis put forward by Erdogan *et al.* thus identifying the cause of dystocia in the present case as uterine adhesion. To the authors' knowledge, this is a unique case of dystocia due to uterine adhesion and its successful surgical management by emergency cesarean section in a goat. It is the first ever case of uterine adhesion as the cause of dystocia reported in goat.

Ethical approval

This article does not contain any studies with human or animal participants performed by any of the authors. The article reports a clinical case presented at the Veterinary Polyclinic, Mannarkkad, Palakkad, Kerala. All protocols followed were as per the guidelines from the standard textbooks in Veterinary Medicine and were ethical.

Reference

1. Youngquist RS, Threlfall WR. Current Therapy in Large Animal Theriogenology-E-Book. Elsevier Health Sciences, 2006.
2. Mcsporrán KD. Dystocia in sheep. Current Therapy in Theriogenology, 2nd ed., WB Saunders, Philadelphia. 1980, 916-918.
3. Sharma VK, Suthar BN, Parsani HR, Ojha SC. A clinical study on dystocia in small ruminants. In XVth Annual Convention and National Symposium on Biotechniques in Optimizing Fertility in Farm Animals. PAU, Ludhiana, Abstracts. 1999; 94:94.
4. Abdul-Rahman LY, Al-Janabi AS, Asofi MK. Study of

- some reproduction aspects of the mature local Iraqi goats. *The Veterinarian*. 2000; 10(1):47-60.
5. Pugh DG, Baird NN. *Sheep & Goat Medicine-E-Book*. Elsevier Health Sciences, 2012.
 6. Franklin JS. *Dystocia and obstetrics in goats. Current Therapy in Theriogenology*, 2nd ed., WB Saunders, Philadelphia, 1986.
 7. Purohit GN. *Proceedings National Seminar on Innovations and Recent Advances in Small Ruminants Production*. Avikanagar, Jaipuri, India. 2006, 227-231.
 8. Naoman UD, Jabbo SS, Ahmed MA, Ahmed AE. Causes and treatment of dystocia in iraqi awassi ewes. *Basrah Journal of Veterinary Research*. 2013; 12(2):250-5.
 9. Aziz DM, Taha MB. Dystocia in Awassi ewes: causes and treatments a review. *Iraqi Journal of Veterinary Science*. 1996; 9(1):1-12.
 10. Noakes DE, Parkinson TJ, England GC. Dystocia and other disorders associated with parturition. Noakes DE, Parkinson TJ, England GCW. *Veterinary Reproduction and Obstetrics*. 2009; 9:207-305.
 11. Brozos CN, Lazarides L, Karagiannis I, Kiossis E, Tsousis G, Psychas V, *et al*. Prolonged dystocia, uterine necrosis, and ovariohysterectomy in a Chios ewe. *Turkish Journal of Veterinary and Animal Sciences*. 2012; 36(2):211-213.
 12. Azawi OI, Omran SN, Hadad JJ. Clinical, bacteriological, and histopathological study of toxic puerperal metritis in Iraqi buffalo. *Journal of dairy science*. 2007; 90(10):4654-4660.
 13. Van der Wal JB, Jeekel J. Biology of the peritoneum in normal homeostasis and after surgical trauma. *Colorectal Disease*. 2007; 9:9-13.
 14. Erdogan G, Ucar EH, Peker C, Kilic N. Prolonged co-twin foetal retention in a sheep: caused by hysterocele ?. *Large Animal Review*. 2015; 21(2):87-89.