



E-ISSN: 2320-7078

P-ISSN: 2349-6800

JEZS 2018; 6(4): 760-761

© 2018 JEZS

Received: 26-05-2018

Accepted: 27-06-2018

Ajay S Satbige

M.V.Sc., PhD (Pursuing)
Assistant Professor (CT),
Department of Veterinary
Medicine, Veterinary College,
KVAFSU, Bidar, Karnataka,
India

NA Patil

PhD, Professor and Head,
Department of Veterinary
Medicine, Veterinary College,
KVAFSU, Bidar, Karnataka,
India

Vaijanath Mammani

M.V.Sc Scholar, Department of
Veterinary Medicine, Veterinary
College, KVAFSU, Bidar,
Karnataka, India

Ravindra BG

PhD Associate Professor,
Department of Veterinary
Medicine, Veterinary College,
KVAFSU, Bidar, Karnataka,
India

Nasal schistosomiasis in a she-buffalo

Ajay S Satbige, NA Patil, Vaijanath Mammani and Ravindra BG

Abstract

A nine year old non-descript she buffalo was presented to Veterinary College Hospital, Bidar during the month of November 2017 with the history of severe epistaxis. Endoscopic examination of nasal cavity revealed pin head sized eruptions and congestion of nasal mucosa. Microscopic examination of nasal washings revealed boomerang –shaped eggs of *S. nasalis* with fully developed miracidium inside. The buffalo was treated with single oral dose of Praziquantel @ 20 mg /kg b.wt along with supportive therapy. The buffalo recovered completely after the treatment.

Keywords: *Schistosoma nasale*, praziquantel, she buffalo

Introduction

Nasal schistosomiasis is a disease affecting mainly large ruminants and to a little extent small ruminants and horses^[1]. The causative blood fluke for Nasal schistosomiasis, *Schistosomiasis nasale* was first identified by Rao in 1933. Nasal schistosomiasis is recognized as the 5th major helminthosis of domestic animals in Indian subcontinent^[2]. This trematode infection is majorly transmitted by fresh water snails belonging to *Indoplanorbis exustus* and *Lymnaea luteola*, carrying *Cercariae indiciae*, larval form of parasite. Shape of the egg is generally referred as Palanquin^[3] or boomerang^[4] with presence of terminal spine. It resides in nasal veins of cattle and buffaloes and adversely affects health and production in affected animals. It causes nasal granuloma and snoring disease among cattle, but only subclinical infection among buffaloes. Clinical signs are less severe in buffaloes than cattle^[5]. The present communication reports the presence of *S. Nasale* infection in a non-descript buffalo.

Materials and Methods

Clinical history

A nine year old non-descript She buffalo presented to the Veterinary College Hospital, Bidar, Karnataka during the month of November 2017 with the history of severe epistaxis. Clinical examination and sample collection endoscopic examination of nasal cavity revealed pin head sized eruptions and congestion of nasal mucosa. Nasal washings were collected in normal saline solution

Microscopic examination of nasal washings

The samples were examined as per Sumanth *et al.*^[2, 2]. The nasal washings were collected in a test tube and 10% potassium hydroxide was added. The contents were boiled for 3 min over flame for loss of mucus. It was cool and centrifuged at 2000 RPM for 3 min. After centrifugation, the supernatant was discarded and the sediment was examined under low power of microscope.

Results

The microscopic examination of nasal washings after processing revealed boomerang shaped eggs with terminal spine and fully developed miracidium inside (fig.1). The eggs belong to *S. nasale* as per standard taxonomic keys given by Soulsby^[6].

The buffalo was treated with a single oral dose of Praziquantel @ 20 mg kg. b. wt. along with supportive therapy. The buffalo recovered completely from epistaxis after 48 hours of treatment.

Correspondence

Ajay S Satbige

M.V.Sc., PhD (Pursuing)
Assistant Professor (CT),
Department of Veterinary
Medicine, Veterinary College,
KVAFSU, Bidar, Karnataka,
India

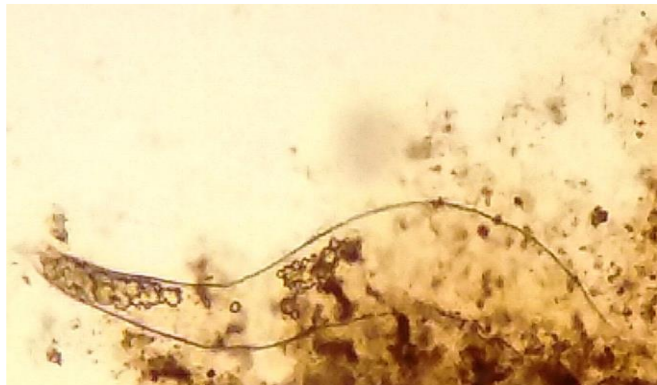


Fig 1: Egg of *Schistosoma nasale* in nasal washings of She buffalo (x100).

Discussion

Nasal schistosomiasis in buffaloes by Rajmohan and Peter [7, 2] and observed only pinhead sized eruptions and congestion of nasal mucosa in affected buffaloes. Similar observations were made in the present case report. Severe epistaxis observed in the present report could be attributed to erosions and congestion of nasal mucosa caused by *S. Nasalis* worm^[5]. Successful treatment with a single oral dose of Praziquantel @ 20 mg/kg b.wt against nasal schistosomiasis in cattle has been reported by Rahman et al^[8] which is in agreement with the result of the present study.

Conclusion

From this study it is concluded that nasal schistosomiasis can be suspected in buffaloes showing signs of severe epistaxis reduced water intake and sudden drop in milk yield, especially in highly irrigated areas. Endoscopic examination of nasal cavity revealed pin head sized eruptions and congestion of nasal mucosa. Hence it is concluded that praziquantel can be effectively used to treat nasal schistosomiasis in buffaloes

Acknowledgments

The authors sincerely thank The Dean, Veterinary College, KVAFSU, Bidar for providing necessary facilities.

References

1. Latchumikanthan A, Pothiappan P, Ilayabharathi D, Das SS, Kumar D, Ilangovan C. Occurrence of *Schistosoma nasale* infection in bullocks of Puducherry. *J Parasit. Dis.* 2014; 38(2):238-240.
2. Sumanth S, D'Souza PE, Jagannath MS. A study of nasal and visceral schistosomosis in cattle slaughtered at an abattoir in Bangalore, South India. *Rev. Sci. Tech. OIE.* 2004; 23(3):937-942
3. Ravindran R, Kumar A. Nasal schistosomiasis among large ruminants in Wayanad, India. *Se. Asian J Trop. Med.* 2012; 43(3):586-588.
4. Sundar N, Kathiresan D, Sivaseelan S, Vairamuthu S, Purushothaman V, Rajavelu R. An outbreak of nasal schistosomiasis among cattle and buffaloes in Tamil Nadu. *Indian J Anim. Sci.* 2004; 74(4):369-370.
5. Banerjee PS, Agrawal MC. Epizootiological studies in bovines on flukes infection with special reference to schistosomiasis. *Ind Vet J* 1992; 69:215-220.
6. Soulsby E.J.L. Helminths, arthropods and protozoa of domesticated animals. 7th edn. Bailliere Tindall. London, 1982.

7. Rajamohan K, Peter CT. Pathology of nasal schistosomiasis in buffaloes. *Kerala J Vet Sci.* 1975; 6:94-100.
8. Rahman SA, Sano M, Jagannath MS, Prabhakar KS, D'Souza PE, Prem G. Efficacy of praziquantel against *Schistosoma nasale* infection in cattle. *Trop Anim Health Prod.* 1988; 20(1):19-22.