



E-ISSN: 2320-7078

P-ISSN: 2349-6800

JEZS 2018; 6(3): 1446-1448

© 2018 JEZS

Received: 16-03-2018

Accepted: 17-04-2018

P Ponnusamy

Dept. of Veterinary Microbiology
Veterinary College and Research
Institute, TANUVAS,
Orathanadu, Thanjavur,
Tamil Nadu, India

M Saravanan

Teaching Veterinary Clinical
Complex, Veterinary College and
Research Institute, TANUVAS,
Orathanadu, Thanjavur,
Tamil Nadu, India

T Lurthu Reetha

Dept. of Veterinary Microbiology
Veterinary College and Research
Institute, TANUVAS,
Orathanadu, Thanjavur,
Tamil Nadu, India

BSM Ronald

Department of Veterinary
Microbiology, Madras Veterinary
College, TANUVAS,
Chennai, Tamil Nadu, India

R Manickam

Dept. of Veterinary Microbiology
Veterinary College and Research
Institute, TANUVAS,
Orathanadu-614 625, Thanjavur,
Tamil Nadu, India

B Puvarajan

Dept. of Veterinary Microbiology
Veterinary College and Research
Institute, TANUVAS,
Orathanadu, Thanjavur,
Tamil Nadu, India

Correspondence

P Ponnusamy

Dept. of Veterinary Microbiology
Veterinary College and Research
Institute, TANUVAS,
Orathanadu, Thanjavur,
Tamil Nadu, India

Curvularia dermatomycosis in a goat: Tamil Nadu, India

P Ponnusamy, M Saravanan, T Lurthu Reetha, BSM Ronald, R Manickam and B Puvarajan

Abstract

A 2 year old female nondescript goat was presented with the history of skin infections such as reddening, crusty and darkened areas. Samples were randomly collected from affected areas aseptically for microbiological examination. Macroscopic and Microscopic examination of colony on sabouraud's dextrose agar revealed cottony and dark brown coloured colony. The reverse is brown to brownish-black in colour. Microscopic examination of colonies by lacto phenol cotton blue staining revealed the presence of septate hyphae with short conidiophores and multicellular, curved conidia. The appearance of surface colonies on sabouraud's dextrose agar as well as in lactophenol cotton blue staining identified the organism as *Curvularia* species. The *Curvularia* species are commonly found on variety of plants. The present communication reports the *Curvularia* sp. skin infections in goat in the Cauvery delta region of Tamil Nadu, India.

Keywords: *Curvularia* species, skin infection, small ruminants, Cauvery Delta region, Tamil Nadu

1. Introduction

Curvularia species are ubiquitous dematiaceous fungi, belongs to class eumycetes and family *Pleosporaceae*. It is widely distributed in the environment and commonly found in soil and vegetation in the tropical and temperate countries [1]. It is commonly associated with disease in plants [2]. There were reports on infections in humans and animals due to some species of *Curvularia* based on route of infection and immune status of the host [3]. The most frequently isolated *Curvularia* species from clinical samples are *C. australiensis*, *C. geniculata*, *C. hawaiiensis*, *C. lunata* and *C. spicifera* [4]. Sivanesan 1987 [5] has reported that *Curvularia* species produce sympodial conidiophores with terminal and intercalary conidiogenous cells. The Conidia are elongated, transversely septate and curved conidia with asymmetrically swollen intermediate cell, however straight conidia producing species also reported. The present paper describes the report of *Curvularia* dermatomycosis in a goat in the Cauvery delta region of Tamil Nadu, India.

2. Materials and Methods

A 2 years old female non-descriptive goat was presented to Teaching Veterinary Clinical Complex, Veterinary College and Research Institute, Orathanadu, Thanjavur district with the history of skin infection and loss of hair in the face. Pruritus, erythema, alopecia and crusts were noticed in the face region on clinical examination. Samples were collected in a sterile container for mycological analysis. The samples were inoculated into Sabouraud's dextrose agar and incubated aerobically at 30 °C for 24 hours. Fungal colonies were observed on inoculated culture plate. Macroscopically, colony growths such as colony texture, color, reverse color and microscopic characters such as color, shape, number of septa and arrangement of conidia were identified. The isolation and identification of fungus was performed by following the guidelines of Al-Doory, 1980 [6].

3. Results

Colonies on Sabouraud's dextrose agar were cottony, grayish in color initially which became dark brown color later on. The reverse side of the culture plate revealed brown to brownish-black colored colonies. Microscopic examination of colonies by lacto phenol cotton blue staining revealed the presence of septate hyphae with short conidiophores and four celled, ovoid brown colored conidia with subterminal cell enlarged and distinctly larger than

remaining cells were observed. The appearance of surface colonies on sabouraud's dextrose agar as well as in

lactophenol cotton blue staining identified the organism as *Curvularia* species.

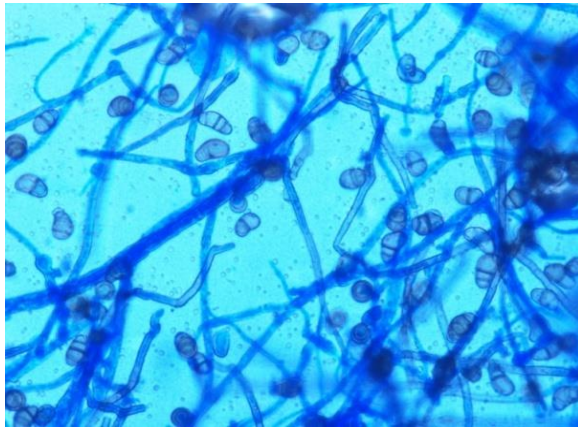


Fig 1

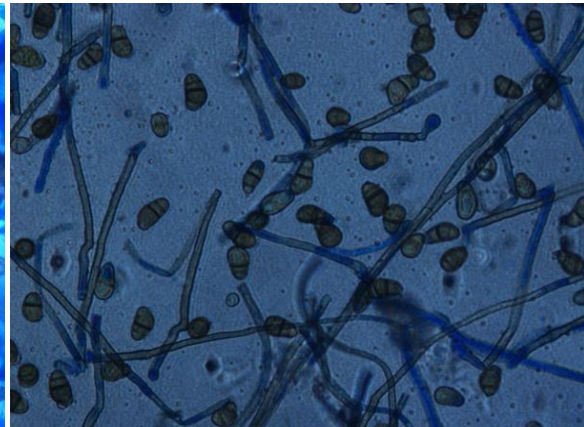


Fig 2

Fig 1 & 2: Microscopic examination (400 X) of *Pithomyces* spp.

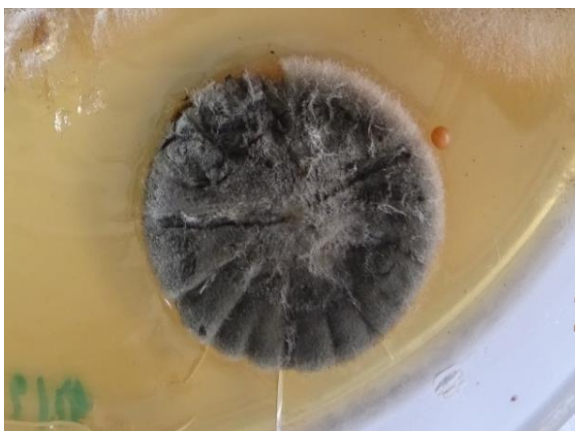

Fig 3: Colony character of *Curvularia* spp. in Sabourauds Dextrose agar

4. Discussion

The macroscopic and microscopic characters were similar to the report of *Curvularia* species shown in the Figure 1, 2 and 3 [7-9]. *Curvularia* species is a common fungus that grows on a wide range of decaying plant material, prevalent in warm and humid areas. The fungus is widely distributed and has been the cause of several infections in human and animals. The main route of infection usually occurs through inhalation and skin inoculation [10]. The *curvularia* species have been linked with many infections in humans such as sinusitis, keratitis, peritonitis, onychomycosis, endocarditis, endophthalmitis, cerebral phaeohyphomycosis [11-14]. Chhabra *et al.*, 2004 reported that *Curvularia* species is a cause of subclinical mastitis in a goat. This species have also been reported to be associated with canine fungal keratitis [15], bovine dermatomycosis [16] and bovine mycotic mastitis [17]. To the best of our knowledge, this is the first report of *Curvularia* spp. from skin infections in goat flocks of Cauvery delta region of Tamil Nadu.

5. Conclusion

The present communication describes the identification of *Curvularia* Species from skin infections in goat. It is concluded that screening of large number of samples suspected of having dermatomycoses in animals and prevalence of this species could help in the development of therapeutic strategies in future.

6. Acknowledgement

The authors are grateful to Tamil Nadu Veterinary and Animal Sciences University (TANUVAS) for providing financial support to carry out this work.

7. References

1. Da Cunha, Sutton DA, Fothergill AW, Gené J, Cano J, Madrid H *et al.* *In vitro* antifungal susceptibility and molecular identity of 99 clinical isolates of the opportunistic fungal genus *Curvularia*. *Diagnostic Microbiology and Infectious Disease*. 2013; 76:168-174.
2. Wilhelmus KR, Jones DB. *Curvularia* keratitis. *Transactions of the American Ophthalmological Society*. 2001; 99:111-30.
3. de Hoog, Guarro J, Gené J, Figueras MJ. *Atlas of clinical fungi*. 2nd edition. Centraalbureau voor Schimmelcultures, Utrecht, The Netherlands, 2000.
4. Krizsan K, Papp T, Manikandan P, Shobana CS, Chandrasekaran M, Vágvölgyi C *et al.* *Clinical Importance of the Genus Curvularia*, 2015, 147-204.
5. Sivanesan A. Graminicolous species of Bipolaris, *Curvularia*, Drechslera, Exserohilum and their teleomorphs. *Mycological Papers*. 1987; 158:154-185.
6. Al-Doory Y. *Laboratory medical mycology*. Lea and Febiger. Philadelphia, 1980.
7. Larone DH. *Medically Important Fungi – A Guide to Identification*. 3rd edition. ASM Press, Washington, D.C, 1995.
8. St-Germain G, Summerbell R. *Identifying Filamentous Fungi – A Clinical Laboratory Handbook*. 1st edition. Star Publishing Company, Belmont, California, 1996.
9. Chhabra D, Arora S, Bagherwal RK. Isolation of *Curvularia* spp. from caprine mastitis. *Indian Veterinary Journal*. 2004; 81(10):1084-1085.
10. Balla A, Pierson J, Hugh J, Wojewoda C, Gibson P, Greene L. Disseminated cutaneous *Curvularia* infection in an immune compromised host: Diagnostic challenges and experience with voriconazole. *Journal of Cutaneous Pathology*. 2016; 43:383-387.
11. Alvarez VC, Guelfand L, Pidone JC, Soloaga R, Ontivero P, Margari A *et al.* Rinosinusitis alérgica fúngica causada por *Curvularia* sp. *Revista Iberoamericana de Micología (Ibero-American Journal of Mycology)*. 2011; 28:104-6.
12. Ehlers JP, Chavala SH, Woodward JA, Postel EA.

- Delayed recalcitrant fungal endophthalmitis secondary to *Curvularia*. Canadian Journal of Ophthalmology. 2011; 46:199–200.
13. Gupta M, Sharma NL, Kanga AK, Mahajan VK, Tegta GR. Onychomycosis: clinicomycologic study of 130 patients from Himachal Pradesh, India. Indian Journal of Dermatology, Venereology and Leprology. 2007; 73:389-92.
 14. Moody MN, Tschen J, Mesko M. Cutaneous *Curvularia* infection of the forearm. Cutis Journal. 2012; 89: 65–8.
 15. Ben-Shlomo G, Plummer C, Barrie K, Brooks D. *Curvularia* keratomycosis in a dog. Veterinary Ophthalmology. 2010; 13:126-130.
 16. Qureshi S, Wani SA, Beg S. *Curvularia* Dermatormycosis in a Jersey Heifer: A Case Report. Pakistan Veterinary Journal. 2006; 26(3):149-150.
 17. Mehrotra PK, Rawat M. Mycotic agents associated with normal and mastitis udder of cows in Bikaner. Indian Journal of Comparative Microbiology Immunology and Infectious Diseases. 1989; 10(3):151-152.