

E-ISSN: 2320-7078

P-ISSN: 2349-6800

www.entomoljournal.com

JEZS 2020; 8(2): 1282-1284

© 2020 JEZS

Received: 10-01-2020

Accepted: 12-02-2020

Mahal JS

Assistant Professor, Department of Veterinary Gynaecology and Obstetrics, Khalsa College of Veterinary and Animal Sciences Amritsar, Punjab, India

Thind AS

Assistant Professor, Department of Veterinary Gynaecology and Obstetrics, Khalsa College of Veterinary and Animal Sciences Amritsar, Punjab, India

Sandhu HS

Assistant Professor, Department of Veterinary Gynaecology and Obstetrics, Khalsa College of Veterinary and Animal Sciences Amritsar, Punjab, India

Corresponding Author:**Mahal JS**

Assistant Professor, Department of Veterinary Gynaecology and Obstetrics, Khalsa College of Veterinary and Animal Sciences Amritsar, Punjab, India

Fetal arthrogyriposis and agnathia associated with hydroallantois in Nili Ravi buffalo

Mahal JS, Thind AS and Sandhu HS

Abstract

A 5 year old Nili Ravi Buffalo was presented with the history of full term gestation, sudden enlargement of abdominal cavity from the last 20 days and having problem while walking and sitting. Per vaginal examination of buffalo revealed that the cervix was closed and on per rectal examination it was observed that there was large amount of fluid in the uterus which occupies the pelvic brim, it was difficult to move hand per rectally. Based on history and clinical examination findings diagnosis of hydroallantois was made. The buffalo was treated with intramuscular cloprostenol sodium 500µg and Dexamethasone 40 mg. After two days of induction revealed four finger dilation of a cervix. Cervical massage was using warm sodium carboxy methyl cellulose (CMC) gel for complete cervical dilation. The oversized fetus was removed from uterus by performing complete fetotomy. It was concluded that cloprostenol sodium and Dexamethasone are effective for the induction of parturition in animals suffering from hydroallantois.

Keywords: Fetal arthrogyriposis, agnathia associated, hydroallantois, Nili Ravi buffalo

Introduction

Hydroallantois is associated with sudden accumulation of abnormal amount of amber coloured watery fluid in allantoic sac of fetal membranes which results into bilateral distension of abdomen. Normal amount of fluid in allantoic cavity is around 20 litres but during hydroallantois it may increase upto 150-260 litres Pak Dairy Info (2020). Hydroallantois is considered as a sporadic disorder of gestation which occurs due to pathological defect in fetal membranes thus considered as a maternal abnormality. The accumulation of fluid in allantoic sac is an instant and rapid process which occurs within 5 to 20 days. It most commonly occurs during last trimester of gestation but can also occur at any time after 5th months of pregnancy Selvaraju *et al.* (2012) [12]. Hydroallantois contributes about 80-90% of total gestational hydropsy conditions Youngquist and Threlfall (2007) [15]. Hydroallantois is associated with abnormal functioning of placentomes due to development of adventitious placentation Drost (2007). In this condition, generally caruncles of one of the horn are initially involved and become nonfunctional which later alters the functioning of rest of the placentomes hence resulting into enlarged and diseased placentomes Srinivas and Sreenu (2006) [13]. The increased permeability of chorioallantoic membrane which may cause decreased active transport of sodium across the chorioallantoic membrane results into hormonal imbalance and fetal renal disease Morin *et al.* (1994) [8]. Excessive accumulation of fluid inside the allantoic cavity might be due to hydronephrosis of fetal kidney which resulted into polyurea Palanisamy *et al.* (2014) [9].

Case History and Diagnosis

A 5 year old Nili Ravi Buffalo was presented to Veterinary Clinical Complex of KCVAS, Amritsar, with the history of full term gestation and sudden enlargement of abdominal cavity from the last 20 days. Animal reduced feed intake along with distended abdomen and had problem while walking and sitting (Fig.1). The udder was tucked up and buffalo was dull and depressed showing signs of difficult breathing, sunken eyes, dry muzzle, congested mucus membrane with normal body temperature 101.4°F, respiration rate 50 per minute and heart rate 80 per minute.

Per vaginal examination of buffalo revealed that there was no post cervical uterine torsion, cervix was closed and on per rectal examination it was observed that there was large amount of fluid in the uterus which occupies the pelvic brim, it was difficult to move hand per rectally. No fetus part and fremitus was observed during per rectal examination.

Treatment and Discussion

The buffalo presented had a closed cervix and was treated with injection Vetmate 2 ml (500µg cloprostenol sodium) intramuscular followed by injection Dexamethasone 40 mg intramuscular. Different treatment protocols such as prostaglandins along with dexamethasone and estrogen preparations have been mostly used for induction of parturition in buffaloes and cattle Kumar *et al.* (2012) [12]. For termination of pregnancy in hydroallantois case animal usually treated with PGF₂α (prostaglandins) and corticosteroids Manokaran *et al.* (2011). After 24 hrs of induction, animal showed signs of parturition and there was expulsion of around 150-180 litres of amber colored plasma like consistency allantoic fluid and to compensate with hypovolemic shock animal was intravenously administered with exogenous fluid therapy consisting of normal saline solution 3 litres with diluted mifex 450 ml (calcium borogluconate) and ringer lactate solution (RL) 5 litres. Supportive fluid therapy is required with continuous and slow removal of excess fluid to avoid hypovolemic shock Peiro *et al.* (2007) [10]. In Hydroallantoic animals dehydration, dullness, depression and sunken eyes are due to shifting of interstitial fluid from cells to cavity Arthur *et al.* (1989) [2].

On per vaginal examination after two days of induction it was found that there is four finger dilation of a cervix. Cervical massage using warm sodium carboxymethyl cellulose (CMC) gel was done to allow full hand cervical dilation. Cervical massage was carried out with 15-30 ml of warm sodium carboxymethyl cellulose gel and repeated after every 30 minutes resulting into complete cervical dilation within 3 hours Ghuman *et al.* (2010) [4]. Cervical massage with 30-40 ml warm carboxymethyl cellulose gel for 5 minutes and repeated after every 30-40 minutes resulted into complete cervical dilation in ring womb ewes within 120-140 minutes Prasad *et al.* (2017) [11]. Cervical massage with warm carboxymethyl cellulose gel is a non-hormonal method for complete cervical dilation Honparkhe *et al.* (2009) [5]. After complete cervical dilation the fetus was palpated which revealed that it was oversized fetus in ventro transverse presentation and left cephalic iliac position along with arthrogryposis and agnathia. It was impossible to drag the fetal limbs into the birth passage due to malposition and limited movement of limbs. So the decision of complete fetotomy was taken which involved six cuts. Complete fetotomy using Thygesen fetotomy was an effective method for per vaginal delivery of fetal parts. The extracted fetus was suffering from congenital disorders like partial agnathia, arthrogryposis and bilateral anophthalmia (Fig. 2) as previously reported in Murrah buffalo calf by Supriya and Rao (2016) [14]. To combat with uterine bleeding injection Zakshot (Carus Laboratories) 20 ml intravenously (i.v.) (tranexamic acid 100mg/ml) was given prior to the fetotomy procedure. During first cut (decapitation) oversized fetus head was removed by episiotomy approximately 1cm on dorsal commissure of vulva. Later on five regular cuts were applied to remove complete fetus from the uterus (Fig. 3). After complete delivery of fetus, some amount of allantoic fluid was retained in the uterus along with fetal membranes. Injection oxytocin (Pfizer) 40 I.U. was given immediately after removal of fetus to counter retained fetal membranes. Supportive therapy was given which includes 10 litres ringer lactate (RL) solution intravenously. Antimicrobial therapy to counter with bacterial infection was given by injection Ampicillin and Cloxacillin 4.5gm (A.C Vet, Intas) intramuscular (i.m.) bid for 5 days

along with inj. Gentamicin (Zydus) 20 ml intramuscularly bid for 5 days and injection metronidazole (Infotek Pharmaceuticals) 1.5 litre I.V. for 3 days.

Injection Repronol- Vitamin E & Selenium (Cadila) 10 ml i.m. o.d. for 5 days for endometrium regeneration and ecobolc syrup (Exapar, Ayurved limited) 250 ml p.o. daily for 3 days. Along with 4 bolus of furea (furazolidone) (Vets Pharma) intrauterine for uterine cleansing. After 12 hours of furea bolus intrauterine manual removal of placental membranes. After 1 week there was uneventful recovery of animal and complete appetite was restored (Fig. 4).

Conclusion

The induction of parturition with cloprostenol sodium and dexamethasone is quite helpful in a hydroallantoic buffalo. Cervical massage with warm sodium carboxymethyl cellulose gel is very effective for complete cervical dilation for per vaginal delivery of fetus.

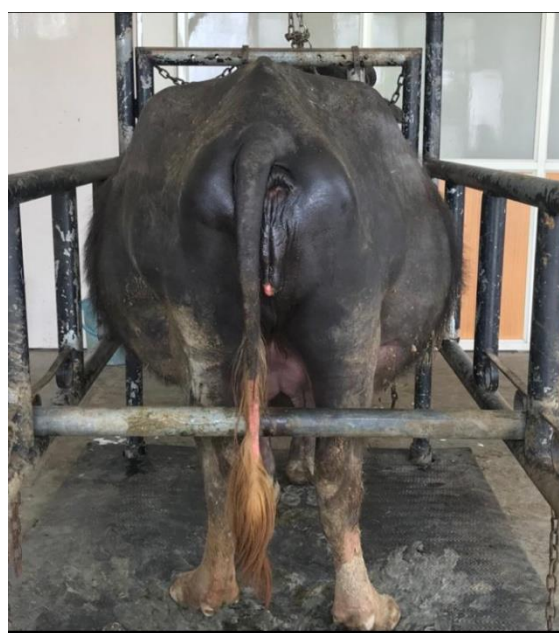


Fig 1: Distended abdomen due to hydroallantois

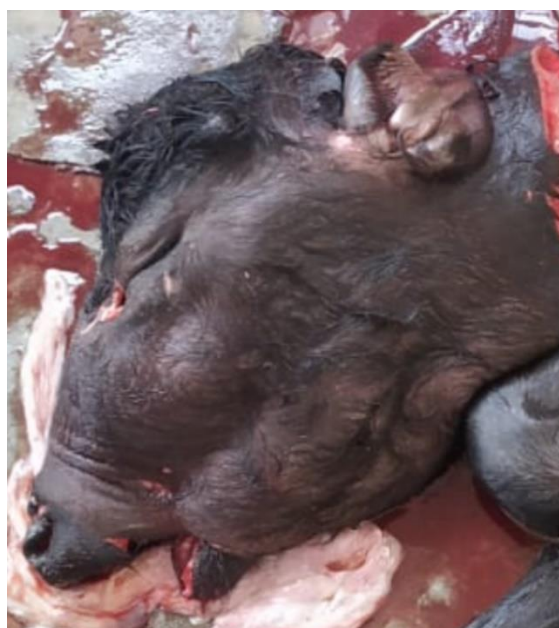

Fig 2: Note oversized fetal head with partial agnathia and bilateral anophthalmia.



Fig 3: Fetal extraction after fetotomy.

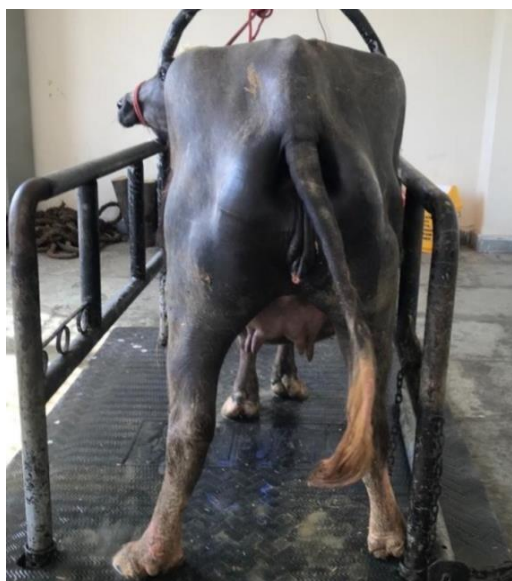

Fig 4: After treatment of hydroallantois.

References

1. Aftab MJ. Hydropsy. Pak Dairy Info. Pakistan's 1st online dairy farming guide. [Http://www.pakdairyinfo.com](http://www.pakdairyinfo.com).2020.
2. Arthur GH, Noakes DE and Pearson H. Veterinary Reproduction and Obstetrics, ELBS, Lucknow, India, 1989, 118-120.
3. Drost M. Complication during gestation in the cow. Theriogenology. 2007; 68:487.
4. Ghuman SPS. Uterine Torsion in Bovines: A review. Indian Veterinary Journal. 2010; 80:289-305.
5. Honaparkhe M, Ghuman SPS, Kumar A, Gupta K, Sood NK, Ahuja CS. Cervical massage with sodium carboxy methyl cellulose for achieving complete cervical for achieving complete cervical dilatation in successfully detorted uterine torsion affected buffaloes. Indian Journal of Animal Sciences. 2009; 79(1):26-29.
6. Kumar P, Sharma A, Singh M, Kumar N. Hydrallantois in Buffalo. Buffalo Bulletin. 2018; 37(3):437-440.
7. Manokaran S, Napoleon RE, Palanisamy M, Selvaraju M, Prakash S. Clinical management of Hydrallantois in a cow using transcervical allantocentesis method: A case report. International journal of Science, Environment and Technology. 2016; 5(4):1888-892.
8. Morin DE, Hornbuckle IT, Rowan LL, Whiteley HE. Hydrallantois in a caprine doe. Journal of American

9. Palanisamy M, Manokaran S, Selvaraju M. Therapeutic Management of Hydrallantois in a Buffalo. Intas Polivet. 2014; 15(2):219-220.
10. Peiro JR, Borges AS, Ynaka R, Koivisto MB, Mendes FLF, Feitosa JO *et al.* Hydrallantois in Ewe (case report). ARS Veterinaria. 2007; 23(2): 116-119.
11. Prashad CB, Srinivas M, Anusha K, Rao KSS. Clinical management of dystocia due to incomplete cervical dilation in Sheep. International Journal of Science, Environment and Technology. 2017; 6(4):2535-538.
12. Selvaraju M, Manokaran S, Palanisamy M, Napoleon RE and Kumar R. Hydroallantois in a buffalo. Indian Journal of Animal Reproduction. 2012; 33: 92-93.
13. Srinivas M and Sreenu M. Hydroallantois with foetal ascites in a Buffalo. Indian Veterinary Journal. 2006; 83(12): 1342-343.
14. Supriya B, Rao TSC. Bilateral uncomplicated anophthalmia in a buffalo calf. Buffalo Bulletin. 2016; 35(4):485-488.
15. Youngquist RS, Threlfall WR. Current Therapy in Large Animal. Theriogenology. 2nd Eds., Saunders Elsevier, St. Louis, Missouri, 2007.