Journal of Entomology and Zoology Studies

Available online at www.entomoljournal.com

E-ISSN: 2320-7078
P-ISSN: 2349-6800
JEZS 2018; 6(3): 462-465

Received: 05-03-2018
Accepted: 06-04-2018

Sangram Ketan Sahoo
ICAR-Central Institute of Freshwater Aquaculture, Kausalyaganga, Bhubaneswar, Odisha, India

Shajahan Ferosekhan
ICAR-Central Institute of Freshwater Aquaculture, Kausalyaganga, Bhubaneswar, Odisha, India

Shiba Shankar Giri
ICAR-Central Institute of Freshwater Aquaculture, Kausalyaganga, Bhubaneswar, Odisha, India

Manoranjan Paramanik
ICAR-Central Institute of Freshwater Aquaculture, Kausalyaganga, Bhubaneswar, Odisha, India

Kalidoss Radhakrishnan
ICAR-Central Institute of Freshwater Aquaculture, Kausalyaganga, Bhubaneswar, Odisha, India

Correspondence
Shajahan Ferosekhan
ICAR-Central Institute of Freshwater Aquaculture, Kausalyaganga, Bhubaneswar, Odisha, India

Reports on common deformities in induced bred *Horabagrus brachysoma* larvae

Sangram Ketan Sahoo, Shajahan Ferosekhan, Shiba Shankar Giri, Manoranjan Paramanik and Kalidoss Radhakrishnan

Abstract
The incidence of deformation in the larvae is considered as a problem as well as possesses economic challenges in the aquaculture industry. The frequency of its incidence ranges from 4-5% during normal larval production in the hatchery. In this study, we tried to segregate and classify the yellow catfish, *Horabagrus brachysoma* deformities. The different type of abnormalities appeared in the larvae were categorised as, teratoma: undifferentiated embryonic mass without any body parts; acephala: larvae possessing undifferentiated head; tunicate: looks like a pigmy, shorter in length compared to normal larvae; humpback: curvature on the notochord at the trunk region; axial deformity: bend in trunk or tail region; compound tetras: larvae possessing multiple curvatures in both trunk and tail. It also observed that these deformed larvae were died within 5-6 days of rearing.

Keywords: Deformity, induced breeding, larvae, larval mortality, yellow catfish

Introduction
Induced spawning of fish by hormonal stimulation is a common practice to get desired number of larvae for its further aquaculture without depending on the natural seed collection. The quality of seed is also assured by this activity through controlled environment and brood management. In spite of these, abnormalities among the larvae are found during embryonic and post embryonic periods of life in fishes. Abnormalities like teratoma, bent in any parts of notochord, loss of one of the parts of body etc. are found during larval [1, 2] or in other life stages [3, 4] of different fish species. These observed malformations are reported due to environmental conditions [5-7], Chemical [8], toxicological [9], diet and nutrition [10] and breeding protocol [2, 11, 12]. *Horabagrus brachysoma* is a species of importance due to ornamental as well as food value [13]. We often encounter deformed larvae even after following the optimal breeding protocol in this catfish [14]. The incidence of such malformed larvae in great number usually reduces the quality as well as quantity of larval production from a hatchery. The present study records and reports on the types of morphological anomalies in the hatchery bred *H. brachysoma* larvae.

Materials and Methods
Induced breeding of *H. brachysoma* was undertaken following a standard protocol to get fertilised eggs [12, 13] during the month of June-September. The fertilised eggs thus obtained during different times were incubated in the flow-through hatchery, where plastic tubs were kept under the water taps. The water supply was maintained with continuous water drops added to the egg incubated tubs without disturbing the eggs. A hole was provided in each tub at the rim for water outlet at the rate of 2-3 L min^{-1}. A total of 200-300 eggs from different breeding attempts were incubated in the tub for hatching. The eggs were allowed for 24-26 hours for hatching. The hatchlings were collected and spreaded in a round rearing tub [14]. The healthy larvae migrated to the periphery of the rearing tank and deformed larvae/embryo remained at the centre. The good larvae and deformed larvae were counted separately for recording their percentage in the population [1, 2]. Different varieties of deformed larvae were segregated using magnifying glass and brought under microscope for photography [1, 15, 16]. Rest of the deformed larvae were reared separately to observe their behaviour and pattern of survival during the rearing operation.

Results

The high incidence of deformity in larvae was recorded during pre and post monsoon breeding operation compared to peak breeding season. The incidence was 4-5% during breeding season compared to 9-13% during the breeding operation in early or late breeding season. The categorisation of deformed larvae, their morphology and behaviour were described as follows.

Normal larvae

The larvae were well differentiated with head, trunk and tail with straight body morphology (Fig. 1a). The larvae were 4-5mm in length. Slow creeping movement with tail lashing was observed just after hatching. The larvae became more active as the yolk sac got absorbed. The larvae showed free swimming behaviour at the age of three days after complete yolk sac absorption. The larvae accepted well to live plankton at this stage.

Teratoma

It was an undifferentiated embryonic mass without any body parts (Fig 1b). This type of embryonic development of fertilised eggs was abundant in breeding operation during the pre and post breeding season. The embryonic development of eggs was ceased within multi cell stage. A cell mass with different shapes was visible in the animal pole, where the yolk sac looked round or compressed. The embryos bearing such stage got putrefied within 24 h of hatching.

Acephala

The larvae in this category did not have differentiated head (Fig. 1c). The head was not visible but well differentiated yolk sac, trunk and tail were retained. These larvae looked shorter (2-3 mm). The embryonic development was normal till gastrulation, but probably there was some imparity in development after this stage, resulting this type of deformity. These larvae did not survive beyond 24 h of hatching.

Tunicate

It looked like a pigmy, shorter in length compared to normal larvae (Fig. 1d & e). The length was about 2 mm shorter than the normal larvae with well differentiated body morphology. However, the larvae were inferior in movement compared to normal hatchlings. These larvae survived 6-7 days after post hatching.

Humpback

A curvature on the notochord at the trunk region was visible giving a shape of concave appearance of the trunk (Fig. f). The larvae were 3-3.5 mm in length. The movement was slow before yolk sac absorption and settled at the bottom of the rearing tank. The larvae possessing this type of deformity did not have efficient swimming power like normal larvae after yolk sac absorption. These larvae survived occasionally beyond 7-8 days post hatching.

Axial deformity

Different types of axial deformity were seen in *H. brachysoma* hatchlings. Curvature or bent in the notochord at trunk or tail region was observed (Fig. g & h). The embryonic development seemed to be normal till "C" shape embryo. There was perhaps faulty development in trunk or tail region at this stage resulting the production of trunk or tail bent larvae. These larvae did not show free movement. They settled at the bottom of the tank showing little tail lashing or at times they showed round creeping movement rather than a straight movement. These larvae survived few days beyond yolk sac absorption.

Compound tetras

The larvae possessing multiple curvatures in both trunk and tail, were considered under this category (Fig. i). The larvae lost their movement and unable to survive beyond 7-10 days of post hatching.

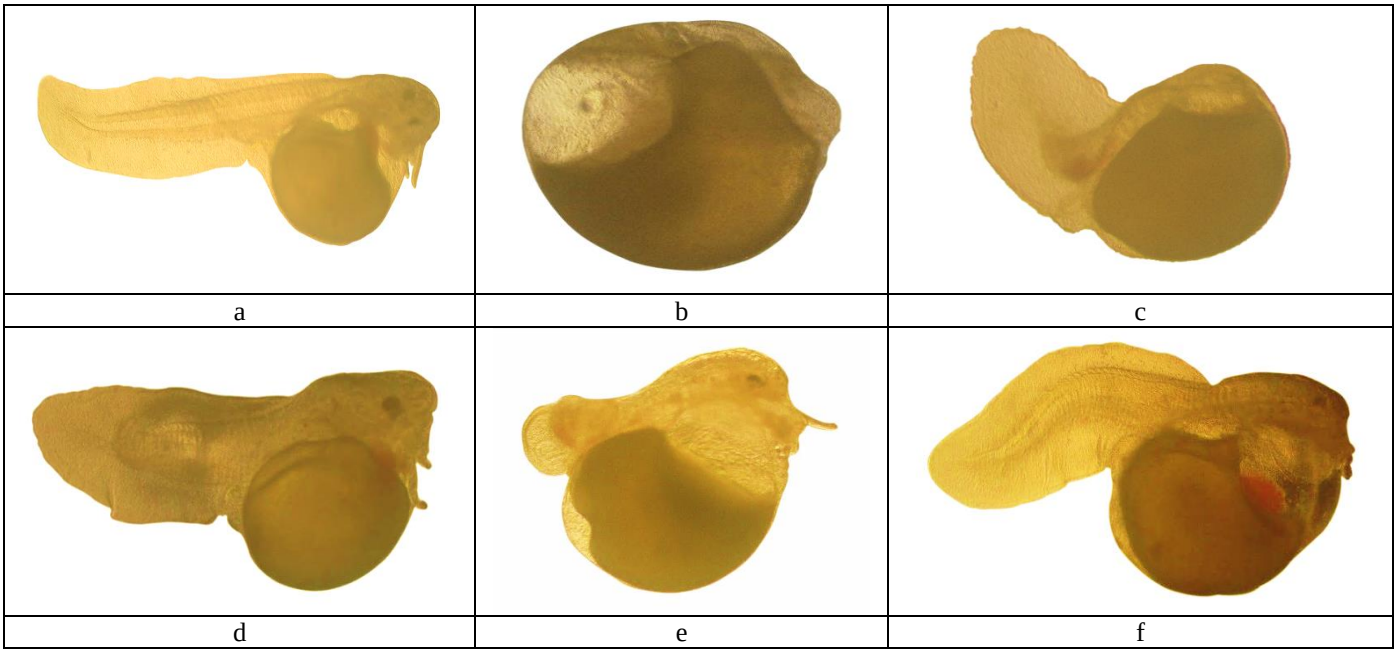

g	h	i

Fig 1: Incidence of common abnormalities encountered among the hatchlings of *Horabagrus brachysoma* during the induced breeding operation.
a. Normal larvae; b. Teratoma; c. Acephala; d. Tunicate 1; e. Tunicate 2; f. hump back; g. Axial deformity 1; h. Axial deformity 2; i. Compound tetra.

Discussion

Induced breeding of *H. brachysoma* proved to be the successful method for high yield of larvae in hatchery condition. But incidence of deformed larvae was also common in this catfish like other hatchery bred fish species [1, 2, 15]. Its occurrence touched as high as 13% during pre and post monsoon periods compared to 5% during prime breeding season. This high incidence might be due to fertilisation of unprime eggs. Similar observation on the incidence of deformed larvae has been reported in carp during off season breeding [1]. The incidence of indeterminate embryonic mass was high during pre and post breeding season. The embryonic development of these eggs might have hampered within gastrulation stage. Hence irregular cell mass with different shape were seen at the animal pole of the egg during hatching. The acephalic condition was probably originated during "C" shape embryogenesis. The deformed larval production due to impaired embryogenesis was also documented by Saha [15]. The causes of deformity in fish were also numerous as reported to be environmental [3, 5] and toxicological [8, 9]. The factors responsible due to above causes can be ruled out as because of the use of pure water having optimal water quality parameters required for hatching of eggs. Hence, faulty embryonic development might be one of the causes for deformation in the present study. The axial deformity in tail or trunk region might be due to faulty vertebral support. The notochordal abnormalities in various forms in different species was reported and resulted due to alteration of collagen metabolism [17], defective connective sheet [18], bent spinal column [3] and defective somite formation [19]. The axial deformed or pigmy larvae did not survive for a longer period after yolk sac absorption. The insufficient acquisition of feed due to inability for free swimming or movement could be the possible reason for early mortality during their rearing. Further study on the identification of the cause responsible during vertebral or somite development may be of great help to reduce the deformed larval production during breeding of this catfish and to maintain the quality of seed for its aquaculture development.

Acknowledgement

The authors are thankful to the Director, ICAR-Central Institute of Freshwater Aquaculture, Bhubaneswar, India for providing the necessary facilities during the study work.

References

1. Rath SC, Gupta SD, Dasgupta S. Common embryonic abnormalities of Indian major carps bred in indoor hatchery systems. Journal of Aquaculture in the Tropics. 1995; 10:193-199.
2. Sahoo SK, Giri SS, Chandra S, Sahu AK. Observation on larval deformity during induced spawning of walking catfish, *Clarias batrachus* (Actinopterygii: Siluriformes: Clariidae), at different combinations of human chorionic gonadotropin dose and latency period. Acta Ichthyologica et Piscatoria. 2009; 39(1):43-45.
3. Backiel T, Kokurewicz B, Ogorzałek A. High incidence of skeletal anomalies in carp, *Cyprinus carpio*, reared in cages in flowing water. Aquaculture. 1984; 43(4):369-380.
4. Daoulas C, Economou AN, Bantavas I. Osteological abnormalities in laboratory reared sea-bass (*Dicentrarchus labrax*) fingerlings. Aquaculture. 1991; 97(2-3):169-180.
5. Bermudes M, Ritar AJ. Effects of temperature on the embryonic development of the striped trumpeter (*Latris lineata* Bloch and Schneider, 1801). Aquaculture. 1999; 176(3-4):245-255.
6. Haddy JA, Pankhurst NW. The effects of salinity on reproductive development, plasma steroid levels, fertilisation and egg survival in black bream *Acanthopagrus butcheri*. Aquaculture. 2000; 188(1-2):115-131.
7. Zelennikov OV. The effect of acidification on oogenesis of rainbow trout during sex differentiation. Journal of Fish Biology. 1997; 50(1):18-21.
8. Klumpp DW, Humphrey C, Huasheng H, Tao F. Toxic contaminants and their biological effects in coastal waters of Xiamen, China.: II. Biomarkers and embryo malformation rates as indicators of pollution stress in fish. Marine Pollution Bulletin. 2002; 44(8):761-769.
9. Von Westernhagen H. Sublethal effects of pollutants on fish eggs and larvae. In Fish physiology, Academic Press. 1998; 11:253-346.
10. Izquierdo MS, Fernandez-Palacios H, Tacon AG. Effect of broodstock nutrition on reproductive performance of fish. Aquaculture. 2001; 197(1-4):25-42.
11. Bonnet E, Fostier A, Bobe J. Characterization of rainbow trout egg quality: A case study using four different breeding protocols, with emphasis on the incidence of embryonic malformations. Theriogenology. 2007; 67(4):786-794.
12. Sahoo SK, Ferosekhan S, Saha A, Giri SS, Paramanik M. Embryonic and larval development of an endangered catfish, *Horabagrus brachysoma*. Indian Journal of Animal Research. 2016; 51(1):15-20.
13. Sahoo SK, Ferosekhan S, Paramanik M, Swain SK. Hatchery Production of the Yellow Catfish *Horabagrus*

brachysoma in India. World Aquaculture. 2014, 52-54.
14. Sahoo SK, Giri SS, Paramanik M, Ferosekhan S. Preliminary observation on the induced breeding and hatchery rearing of an endangered catfish, *Horabagrus brachysoma* (Gunther). International Journal of Fisheries and Aquatics Studies. 2014; 1:117-120.
15. Saha JN. Developmental abnormalities in silver carp, *Hypophthalmichthys molitrix* (Val.). Journal of Aquaculture in the Tropics. 1992; 2:36-41.
16. Sahoo SK, Giri SS, Paramanik M, Ferosekhan S. Larval age at stocking, growth, and survival during fingerling production of the endangered sun catfish, *Horabagrus brachysoma*. Journal of Applied Aquaculture. 2015; 27(2):144-149.
17. Schultz TW, Dumont JN, Epler RG. The embryotoxic and osteolathyrogenic effects of semicarbazide. Toxicology. 1985; 36(2-3):183-198.
18. Sanatamaría JA, Andrades JA, Herráez P, Fernández-Llebrez P, Becerra J. Perinotochordal connective sheet of gilthead sea bream larvae (*Sparus aurata*, L.) affected by axial malformations: an histochemical and immunocytochemical study. The Anatomical Record. 1994; 240(2):248-254.
19. Van Eeden FJ, Granato M, Schach U, Brand M, Furutani-Seiki M, Haffter P *et al*. Mutations affecting somite formation and patterning in the zebrafish, *Danio rerio*. Development. 1996; 123(1):153-164.